
Entropion

CLINICAL REVIEW

AYYAD ZARTASHT KHAN

ayyad.zartasht.khan@so-hf.no

Department of Ophthalmology

Østfold Hospital Trust

Author contribution: first draft of the manuscript, literature search, revision of the manuscript and approval of the submitted version of the manuscript.

Ayyad Zartasht Khan, PhD in regenerative medicine, experience in plastic surgery and specialty registrar in ophthalmology.

The author has completed the ICMJE form and declares the following conflicts of interest: He has ownership interests in the Eye Health Clinic and Dry Eye Clinic, which offer oculoplastic surgery, and gives lectures for and/or receives financial support from Abigo, Alcon, Allergan, AMWO, Bausch & Lomb, Bayer, European School for Advanced Studies in Ophthalmology, Innz Medical, Medilens Nordic, Medistim, Novartis, Santen, Specsavers, Shire Pharmaceuticals and Théa Laboratories.

HANS OLAV UELAND

Department of Ophthalmology

Haukeland University Hospital

Author contribution: literature search, revision of the manuscript and approval of the submitted version of the manuscript.

Hans Olav Ueland, PhD in oculoplastic surgery and specialist in ophthalmology, senior consultant and postdoctoral fellow.

The author has completed the ICMJE form and declares the following conflicts of interest: He is the lead in a multicentre study funded by Klinbeforsk and the Norwegian Thyroid Association. The drugs in this study are paid for by Pfizer.

ELIN BOHMAN

Department of Clinical Neuroscience

Division of Eye and Vision

Karolinska Institute
and
Clinic 1
Section for Eye, Tear Duct and Orbital Surgery
St Erik Eye Hospital

Author contribution: literature search, revision of the manuscript and approval of the submitted version of the manuscript.

Elin Bohman, PhD in oculoplastic surgery, specialist in ophthalmology and head of section (St Erik Eye Hospital).

The author has completed the **ICMJE form** and declares the following conflicts of interest: She has received lecture fees from Santen Sweden.

KIM ALEXANDER TØNSETH

Department of Plastic and Reconstructive Surgery
Oslo University Hospital
and

Institute of Clinical Medicine
University of Oslo

Author contribution: literature search, revision of the manuscript and approval of the submitted version of the manuscript.

Kim Alexander Tønseth, specialist in plastic surgery, head of division and professor of plastic surgery.

The author has completed the **ICMJE form** and declares no conflicts of interest.

TOR PAASKE UTHEIM

Department of Ophthalmology
Drammen Hospital
Vestre Viken
and

Department of Ophthalmology
Oslo University Hospital
and

Department of Ophthalmology
Stavanger University Hospital
and

Department of Ophthalmology
Sørlandet Hospital, Arendal
and

Department of Ophthalmology
Vestfold Hospital Trust, Tønsberg
and

Department of Ophthalmology
Østfold Hospital Trust

Author contribution: literature search, revision of the manuscript and approval of the submitted version of the manuscript.

Tor Paaske Utheim, specialist in ophthalmology, head of research and innovation, and professor of ophthalmology.

The author has completed the ICMJE form and declares the following conflicts of interest: He has ownership interests in the Eye Health Clinic and Dry Eye Clinic, which offer oculoplastic surgery, and gives lectures for and/or receives financial support from Abigo, Alcon, Allergan, AMWO, Bausch & Lomb, Bayer, European School for Advanced Studies in Ophthalmology, Innz Medical, Medilens Nordic, Medistim, Novartis, Santen, Specsavers, Shire Pharmaceuticals and Théa Laboratories.

Entropion, or the inward turning of the eyelid, is common, particularly in older patients. The condition is classified as involutional, cicatricial, spastic or congenital. Involutional entropion is most common and typically treated with lateral tarsal strip, which may be combined with other techniques for eyelid eversion. This clinical review looks at the pathology, diagnostic evaluation and principles for treating entropion.

Entropion is a condition in which the eyelid (almost always the lower eyelid) turns inwards (1, 2). This can lead to corneal irritation and cause symptoms such as foreign body sensation, tearing and redness. It is unsurprising that over 70 % of patients concurrently have dry eyes (3). Entropion can lead to chronic/recurrent conjunctivitis. Extreme cases can result in corneal ulceration and/or perforation (1). Entropion affects approximately 3 % of the population aged over 65 years. The prevalence increases with age and is more common in women than men (3). However, entropion is less common than ectropion (4, 5), a condition in which the eyelid turns outwards. Bilateral entropion is more common than unilateral entropion (3).

Subtype and severity will determine how and when entropion is treated. In this article, we aim to provide an overview of entropion and current treatment. The article is based on a discretionary literature selection and the authors' own clinical experience.

Differential diagnoses

Entropion should not be confused with other conditions with a similar presentation which require different management, in particular epiblepharon, trichiasis and distichiasis (5). Epiblepharon is a congenital condition in which an extra lower eyelid fold pushes the eyelashes upwards to rub against the cornea and is often seen in children of East Asian or Latin American descent. Most people outgrow the condition. In trichiasis, there is malposition of the

eyelashes, which are misdirected and grow vertically, unlike in entropion where it is the eyelid itself that is turned inwards. In distichiasis, there is aberrant growth of the eyelashes from the orifices of the meibomian glands.

Anatomy

The main structures involved in maintaining lower eyelid tone and stability are the lower tarsal plate, the lower eyelid retractors, the orbicularis oculi muscle and the canthal ligaments (6). The most common causes of entropion are loss of horizontal tone of the lower eyelid and dehiscence of the lower eyelid retractors from the lower tarsal plate, leading to instability of the lower eyelid. Figure 1 illustrates the periorbital anatomy in involutional (age-related) entropion.

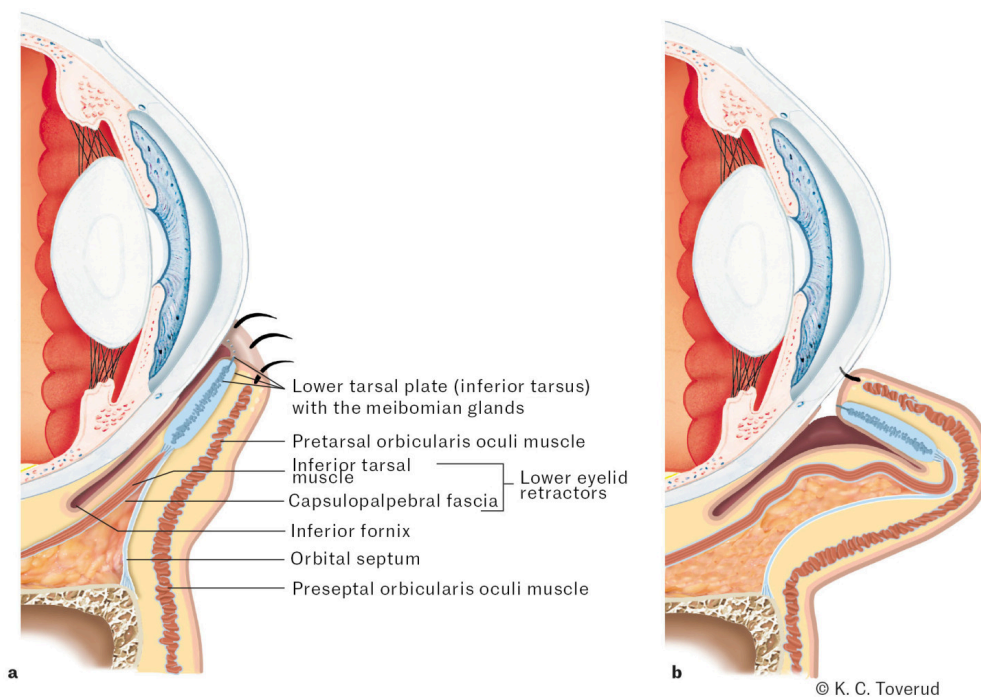


Figure 1 Periorbital anatomy in involutional (age-related) entropion. The figure shows how a stable tarsal plate and tight eyelid retractors (primarily capsulopalpebral fascia and inferior tarsal muscle) contribute to normal lower eyelid anatomy (a) and how laxity of these structures causes entropion (b).

Subtypes

Entropion is classified as involutional (age-related), cicatricial (scar-related), spastic and congenital (5).

The involutional type is most common (1) and is caused by one or more of the following mechanisms: (i) imbalance between the anterior and posterior lamellae of the eyelid; (ii) laxity of the lower eyelid retractors or dehiscence of these from the lower tarsal plate; (iii) laxity of the canthal ligaments; (iv) mismatch between the preseptal and pretarsal portions of the orbicularis oculi muscle so that the preseptal portion overrides the pretarsal portion and thus

turns the lower eyelid inwards; and (v) connective tissue defects and/or lower tarsal atrophy, for example due to ageing and ageing processes. What these mechanisms have in common is inward turning (involution) of the eyelid.

Cicatricial entropion is caused by a vertical shortening of the posterior lid lamella, often secondary to an inflammatory process that produces scarring and contracture of the conjunctiva. Examples of such processes are infections, trauma (including chemical), ocular pemphigoid, Stevens-Johnson syndrome or use of eye drops for glaucoma, which induce conjunctival irritation and scarring (7, 8). Cicatricial entropion can be difficult to treat. Attempts should be made to control and optimise treatment of underlying conditions prior to considering surgical correction.

The spastic subtype is often transient and caused by irritation of the cornea or eyelids, often in connection with eye surgery, blepharitis, infection or trauma. Irritation incites swelling of the eyelid and spasm of the orbicularis oculi muscle (1), leading the preseptal portion of the orbicularis oculi muscle to roll over the pretarsal portion, which results in entropion. This can set off a vicious cycle of more irritation, swelling and spasm of the orbicularis oculi muscle.

Congenital entropion is very rare, and its main cause is disinsertion of the lower eyelid retractors from the lower tarsal plate. Treatment is tailored to the individual patient.

Examination

Examination generally focuses on the lower eyelid. In our experience, entropion almost never affects the upper eyelid, since the tarsus here is larger and more stable. In the event of upper eyelid entropion, scarring should be suspected, and the patient should be examined for conjunctival disease, tumour, pemphigoid and other possible explanations.

The congenital subtype is so rare that examination for it will not be discussed in this clinical review. Spastic entropion will be easy to recognise, since there is likely to be an obvious precipitating cause. Therefore, in practice, the aim of the clinical examination of patients with entropion will be to distinguish between the cicatricial or involutinal subtypes. Consequently, it is vital to examine the conjunctival side of the lower eyelid. Identification of scarring or symblepharon (adhesions between the eyelid and eyeball) on the conjunctival side of the lower eyelid or in the inferior fornix is indicative of cicatricial entropion, while absence of these points to involutinal entropion.

Entropion can be intermittent in some patients (9), in which case the patient will typically report symptoms of eye irritation that come and go. Since intermittent entropion will not necessarily be present at the time of the examination, the condition may remain undiagnosed and lead to considerable corneal injury and vision impairment. In these cases, it can be useful to ask the patient to tightly close their eye to see if that elicits entropion. Faria-E-Sousa et al. discuss a specific test for intermittent entropion (9), but this is outside the scope of our review.

Other potentially useful tests are the forward distraction test (also known as the pinch test), the snap-back test and the lateral distraction test.

The forward distraction test assesses the horizontal (anteroposterior) laxity of the lower eyelid. A pincer grip is used to carefully pull the lower eyelid horizontally, just below the eyelashes. It is generally abnormal if the eyelid can be pulled more than 6 mm away from the eyeball, and this indicates horizontal laxity of the lower eyelid (which is seen in involutional entropion, but also in ectropion).

In the snap-back test, the lower eyelid is pulled downwards with a finger and released without the patient blinking. Normally, the eyelid will immediately snap back to its correct position close to the eyeball. If the test is positive, the eyelid will be slow to return to its original position (possibly with the aid of a blink), which indicates abnormal vertical laxity of the eyelid. The forward distraction test and snap-back test are likely to be normal in cicatricial entropion, but positive in involutional entropion since the pathophysiology of the various subtypes is different.

The lateral distraction test assesses abnormal laxity in the medial canthal ligament. A finger is used to pull the lateral eyelid margin temporally (laterally) while observing the medial punctum. The test is positive (abnormal) if this pulling causes lateral displacement of the medial punctum past an imaginary vertical line that is tangential to the medial limbus. The test can also be used to visualise how the lower eyelid will sit against the eyeball if lateral tarsal strip is performed.

It should be noted that all these tests are of little value in isolation and must be interpreted in conjunction with other clinical findings.

Treatment

Patients with entropion should be referred to a specialist if their condition is symptomatic or the cornea is at risk. In our experience, nearly all patients who are referred for entropion will undergo surgery. This is to avoid the risk of corneal injury associated with untreated entropion. Lack of subjective symptoms in patients with entropion is not a contraindication to surgery. In fact, it could indicate reduced corneal sensitivity, which we believe is an indication for prompt surgical correction. While awaiting surgical intervention, temporary reversal of lower lid inversion can be attempted using tape or strips that are applied to the eyelid in the correct position [\(10\)](#). The patient should be advised to use other non-surgical treatments, such as artificial tears/ophthalmic ointment to prevent corneal injury and to pluck eyelashes if they rub against the cornea.

The treatment of entropion is tailored to the individual circumstances and will depend on the examination findings, subtype, comorbidities and how comfortable the patient is with the extensiveness of a procedure.

For involutional entropion, most textbooks will recommend lateral tarsal strip combined with one or more of the following techniques: retractor tightening, Wies procedure or Quickert sutures. Lateral tightening has previously been described and illustrated in the Journal of the Norwegian Medical Association (4). Retractor tightening involves suturing the inferior part of the lower tarsal plate to the lower eyelid retractors using absorbable sutures. Quickert sutures (also known as everting sutures) are double-armed sutures placed starting from the inferior fornix and tied on the skin side just below the lash line (cilia) to evert the lower eyelid.

Cicatricial entropion is generally induced by underlying pathological conditions which should be managed before surgical intervention. This applies particularly to entropion occurring secondary to ocular pemphigoid and Stevens-Johnson syndrome. Mild forms of cicatricial entropion can be treated with tarsotomy, in which a horizontal incision is made in the tarsus from the conjunctival side, which will slightly increase the vertical length of the posterior lamella. Severe cases often require reconstruction with a graft, such as cartilage or mucous membrane (11). This type of entropion can be extremely challenging to treat and often requires repeated surgeries.

Spastic entropion is typically triggered by a cause that requires investigation. If the condition persists, a good effect can be achieved by injection of botulinum toxin into the preseptal orbicularis oculi muscle (12). The procedures described for involutional entropion may also be appropriate.

Treatment of congenital entropion should take place in a specialist department.

Conclusion

Entropion is a common condition, particularly in older patients. It is classified as involutional (age-related), cicatricial (scar-related), spastic or congenital. Treatment is selected on the basis of aetiology and subtype. Temporary measures should be considered to prevent corneal injury in patients awaiting surgical correction.

We would like to thank Tore Steinkjer for linguistic review of the text in Norwegian.

The article has been peer-reviewed.

REFERENCES

1. Gladstone GJ, Nesi FA, Black EH. Oculoplastic Surgery Atlas. Berlin: Springer, 2002.
2. Tyers AG, Collin J. Colour atlas of ophthalmic plastic surgery. Amsterdam: Elsevier Health Sciences, 2017.
3. Damasceno RW, Osaki MH, Dantas PEC et al. Involutional entropion and ectropion of the lower eyelid: prevalence and associated risk factors in the

elderly population. *Ophthalmic Plast Reconstr Surg* 2011; 27: 317–20. [PubMed][CrossRef]

4. Khan AZ, Ueland HO, Bohman E et al. Ektropion. *Tidsskr Nor Legeforen* 2024; 144. doi: 10.4045/tidsskr.23.0309. [PubMed][CrossRef]
5. Nerad JA. *Techniques in ophthalmic plastic surgery: a personal tutorial*. Amsterdam: Elsevier Health Sciences, 2020.
6. Moore KL, Dalley AF, Agur AMR. *Clinically oriented anatomy*. Riverwoods, IL: Wolters Kluwer india Pvt Ltd, 2018.
7. Singh S, Donthineni PR, Shanbhag SS et al. Drug induced cicatrizing conjunctivitis: A case series with review of etiopathogenesis, diagnosis and management. *Ocul Surf* 2022; 24: 83–92. [PubMed][CrossRef]
8. Adewara B, Singh S. Severe cicatricial entropion repair using mucous membrane graft in Stevens-Johnson syndrome. *Indian J Ophthalmol* 2022; 70: 4470. [PubMed][CrossRef]
9. Faria-E-Sousa SJ, de Paula Gomes Vieira M, Silva JV. Uncovering intermittent entropion. *Clin Ophthalmol* 2013; 7: 385–8. [PubMed]
10. Puri P. Tissue glue aided lid repositioning in temporary management of involutional entropion. *Eur J Ophthalmol* 2001; 11: 211–4. [PubMed]
11. Singh S, Malhotra R, Watson SL. Mucous membrane grafting for cicatricial entropion repair: review of surgical techniques and outcomes. *Orbit* 2024; 43: 539–48. [PubMed][CrossRef]
12. Steel DH, Hoh HB, Harrad RA et al. Botulinum toxin for the temporary treatment of involutional lower lid entropion: a clinical and morphological study. *Eye (Lond)* 1997; 11: 472–5. [PubMed][CrossRef]

Publisert: 16 December 2024. *Tidsskr Nor Legeforen*. DOI: 10.4045/tidsskr.24.0191

Received 5.4.2024, first revision submitted 28.9.2024, accepted 29.10.2024.

Published under open access CC BY-ND. Downloaded from tidsskriftet.no 19 June 2026.