
Myotonic dystrophy type 1 – a multiorgan disorder

CLINICAL REVIEW

KRISTIN ØRSTAVIK

krorstav@ous-hf.no

Section for Rare Neuromuscular Disorders

Oslo University Hospital

Unit for Congenital and Hereditary Neuromuscular Disorders

Oslo University Hospital

Department of Neurology

Oslo University Hospital

Author contribution: idea, draft of manuscript, collection of input, editing manuscript and approval of the submitted version.

Kristin Ørstavik, MD, PhD, specialist in neurology and clinical neurophysiology and head of section. She has extensive experience in the follow-up and treatment of patients with rare neuromuscular disorders and is a supervisor in several PhD studies on myotonic dystrophy type 1. The author has completed the ICMJE form and declares no conflicts of interest.

GRO SOLBAKKEN

Department of Neurology, Rheumatology and Rehabilitation Drammen Hospital, Vestre Viken

Author contribution: manuscript input, editing manuscript and approval of the submitted version.

Gro Solbakken, PhD, specialised physiotherapist, specialist in neurological physiotherapy. She has extensive experience in interdisciplinary follow-up of patients with rare neuromuscular disorders, and her doctoral thesis was on myotonic dystrophy type 1.

The author has completed the ICMJE form and declares no conflicts of interest.

MAGNHILD RASMUSSEN

Department of Paediatric Neurology Oslo University Hospital and
Unit for Congenital and Hereditary Neuromuscular Disorders
Oslo University Hospital,

Author contribution: manuscript input, editing manuscript and approval
of the submitted version.

Magnhild Rasmussen, MD, PhD, specialist in paediatric medicine. She
has specialised expertise in rare hereditary neuromuscular disorders and
has conducted a study on patients with myotonic dystrophy type 1. She is
semi-retired and holds a part-time position.

The author has completed the ICMJE form and declares no conflicts of
interest.

PETTER SCHANDL SANAKER

Department of Neurology
Haukeland University Hospital

Author contribution: manuscript input, editing manuscript and approval
of the submitted version.

Petter Schandl Sanaker, MD, PhD, specialist in neurology, with extensive
experience with patients with rare neuromuscular disorders.

The author has completed the ICMJE form and declares no conflicts of
interest.

HANNE LUDT FOSSMO

Unit for Congenital and Hereditary Neuromuscular Disorders
Oslo University Hospital and
Vikersund Rehabilitation Centre

Author contribution: manuscript input, editing manuscript and approval
of the submitted version.

Hanne Ludt Fossmo, specialised physiotherapist, and PhD candidate
studying myotonic dystrophy type 1. She has extensive experience with
this patient group.

The author has completed the ICMJE form and declares no conflicts of
interest.

EINAR BRYNE

Paediatric Rehabilitation
Vestfold Hospital Trust, Tønsberg

Author contribution: manuscript input, editing manuscript and approval
of the submitted version.

Einar Bryne, senior consultant and specialist in paediatric medicine. He
has extensive experience with children and adolescents with myotonic
dystrophy type 1.

The author has completed the ICMJE form and declares no conflicts of
interest.

TORILL KNUTSEN-ØY

Tønsberg

Author contribution: manuscript input, editing manuscript and approval of the submitted version.

Torill Knutsen-Øy, family caregiver, and author of the book about her experiences, *Alene, sammen*. She was formerly employed in the Unit for Congenital and Hereditary Neuromuscular Disorders and contributed to the development of a handbook for family members of patients with myotonic dystrophy type 1.

The author has completed the ICMJE form and declares no conflicts of interest.

TONJE ELGSÅS

Frambu Resource Centre for Rare Diagnoses

Author contribution: manuscript input, editing manuscript and approval of the submitted version.

Tonje Elgsås, psychologist, specialised in habilitation psychology. She has extensive experience with patients with myotonic dystrophy type 1.

The author has completed the ICMJE form and declares no conflicts of interest.

ARVID HEIBERG

Oslo

Author contribution: manuscript input, editing manuscript and approval of the submitted version.

Arvid Heiberg, MD, specialist in medical genetics and professor emeritus. He has extensive experience with rare disorders and has published a study on the role of family members of patients with myotonic dystrophy type 1.

The author has completed the ICMJE form and declares no conflicts of interest.

Myotonic dystrophy type 1 is an autosomal dominant, inherited multiorgan disorder that can affect people of all ages. It is the most prevalent inherited muscular disease in adults. Late diagnosis points to limited knowledge among the medical community that symptoms other than typical muscular symptoms can dominate. The condition often worsens with each generation and some families are severely affected. Significantly delayed diagnosis means a risk of more serious development of the disorder and

inadequate symptomatic treatment. We hope that this clinical review article may lead to more rapid diagnosis and better follow-up of this patient group.

Myotonic dystrophy type 1, also known as Steinert disease, was first described in 1909 by Joseph Steinert. The prevalence varies considerably throughout the world, with an average of 9.3/100 000, according to a literature review (1). The prevalence in Norway is not certain, but a prevalence study from Northern Norway reports a rate of 13.4/100 000 (2). The main symptoms are often related to muscle stiffness and impaired relaxation of muscles (due to myotonia) and muscle weakness (due to dystrophy). Myotonia typically improves with activity (warm-up phenomenon). Myotonic dystrophy type 1 is a multiorgan disorder with symptoms and findings that may be more prominent than the muscular symptoms would suggest (Figure 1).

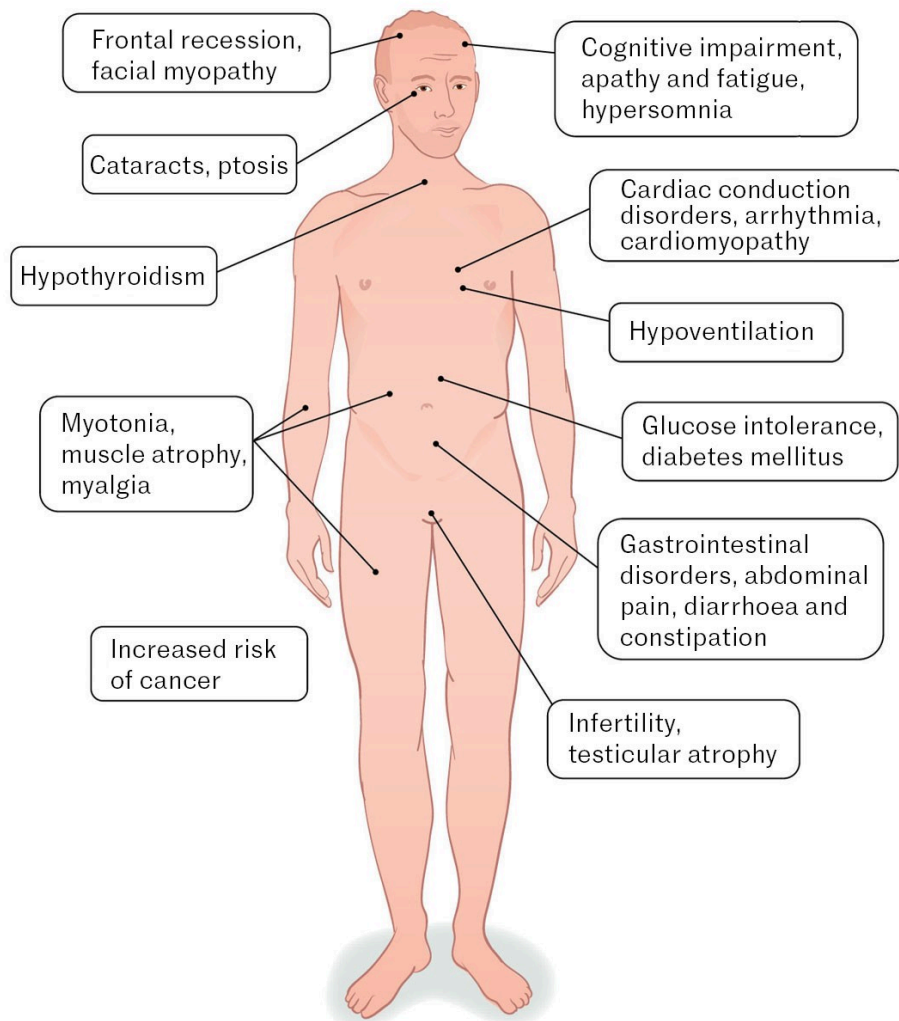


Figure 1 Myotonic dystrophy type 1 is a multiorgan disorder. The figure shows the organ systems that can be affected.

Differential diagnoses include myotonic dystrophy type 2, which is also dominantly inherited, presents with both myotonia and muscular dystrophy, and leads to an increased risk of cataracts and diabetes. However, there is currently no evidence that the condition worsens with each generation.

Symptoms typically start in adulthood, and proximal myopathy dominates. Myotonic dystrophy type 2 is rarer than type 1, with a prevalence of 2.3/100 000 (1). In this article, we focus on myotonic dystrophy type 1. Other important differential diagnoses are myotonia congenita, which presents with myotonia but not myopathy. In adolescents and adults, distal myopathies can also resemble myotonic dystrophy type 1, but these typically do not present with ptosis and facial myopathy as seen in myotonic dystrophy type 1.

This clinical review is based on a purposive sample of international literature, Scandinavian and international recommendations, and the authors' specialised knowledge of the patient group through clinical work, research and personal experiences as family members of a patient with myotonic dystrophy type 1. A review of this type does not cover the entire topic, but there are good international guidelines for diagnosis and follow-up that demonstrate the extent of this disorder (3–5).

Genetics

As described in 1992, myotonic dystrophy type 1 is caused by an unstable expansion of a CTG repeat in the dystrophin myotonia protein kinase (DMPK) gene (6), and is classified as a trinucleotide repeat disorder. Unaffected individuals have 5–37 repeats of the CTG complex. Repeats in the so-called premutation range (38–49 repeats) tend to slowly increase to the pathogenic range (more than 50) over generations. Repeats above 50 and up to more than several thousand are pathogenic. The instability and size of the repeat increases with age, and the number of repeats also typically increases when passed from parent to child, thus resulting in the disease phenotype becoming more severe in successive generations (anticipation) (7).

Subgroups

Myotonic dystrophy type 1 is divided into five subgroups depending on symptom onset (8). *Congenital* onset manifests at birth or during the neonatal period and is usually inherited from the mother. The child is hypotonic and often experiences difficulties with breathing and feeding. Some are born with clubfeet. Genetically, there are normally more than 750 repeats. Some of the children die during the neonatal period. Most others show motor improvement after the neonatal period but often have significant cognitive impairment. The motor difficulties gradually worsen again, as in classic myotonic dystrophy type 1.

Infantile onset presents before the age of ten. The initial symptoms are typically associated with delayed psychomotor development, learning or behavioural difficulties and mild motor symptoms (9). *Juvenile* onset presents between the ages of 10 and 18 years and typically involves social and learning difficulties, motor symptoms, myotonia and the development of muscle weakness (10). *Classic* adult onset presents after the age of 18, typically

involving motor symptoms but can also include abdominal pain, hypersomnia, cardiac symptoms or cataracts (8, 11). *Late* adult onset presents after the age of 40, and these individuals often have cataracts and possibly mild motor symptoms (11).

Diagnosis

Studies have shown considerable delays in the diagnosis of patients with myotonic dystrophy type 1. For patients with symptom onset before the age of 18, a US survey from 2013 revealed an average delay of 13 years between the first symptom and receiving a diagnosis (12).

Myotonic dystrophy type 1 is diagnosed by genetic testing. This test is not included in the gene panels used to diagnose neuromuscular disorders and must be ordered separately. Genetic testing should be considered as part of the investigation of behavioural, attentional and/or significant learning difficulties in children, including for those without other obvious symptoms and signs of myotonic dystrophy type 1. Motor symptoms can be subtle in children and young people with early cognitive impairment associated with the disorder. Adult patients with early bilateral cataracts, muscle stiffness or progressive daytime fatigue and lack of motivation should also be assessed, especially those with a positive family history. Muscle biopsy is not typically part of the diagnostic procedure, but if performed as part of a general investigation for myopathy, it can show characteristic findings. Creatine kinase (CK) levels can be normal or slightly elevated, while electromyography (EMG) can detect myotonia and myopathy even if this is not observed during clinical examination.

Myopathy and myotonia

In myotonic dystrophy type 1, there is typically muscle involvement, with distal atrophy of the extremities and the face, weakness in the hands and forearms, and many patients develop foot drop. Ptosis, reduced facial expression (myopathic facies) and atrophy of the temporal muscle are often observed in the face (8). Reduced facial expression can lead to misinterpretation of facial expressions. Early neck muscle involvement may be observed in adults, and a recent Norwegian study showed that this also applies to abdominal and back muscles in many cases (13). The muscles in the throat and around the mouth often become myopathic, resulting in slurred speech as well as problems with chewing and swallowing. These problems can also have a myotonic component.

Myotonia is otherwise typically observed in the hands in the form of problems releasing a grip or when shaking hands. Testing can entail asking the patient to clench their fist tightly and release it quickly, or thenar muscle percussion. Muscle weakness and poor balance often lead to falls. In neonates with the

congenital variant, hypotonia and delayed motor development are typically observed. Dysarthria and reduced facial expression can be typical features of myotonic dystrophy type 1 in children.

Cardiac and respiratory involvement

Patients with myotonic dystrophy type 1 have a reduced average life expectancy, with one literature review giving the average age of death as the mid-fifties (14). Respiratory dysfunction is considered the primary cause of death, but cardiac involvement also constitutes a significant risk factor for premature death (14). Cardiac involvement is described in up to 80 % of adults with myotonic dystrophy type 1 and can present as various arrhythmias, cardiomyopathy and sudden cardiac death (15). The international recommendation is annual electrocardiography (ECG) as well as Holter monitoring and echocardiography when symptoms occur (16).

Respiration can be affected in several ways (17). Patients may experience classic obstructive sleep apnoea due to weakness of the upper respiratory muscles. They may exhibit a restrictive pattern due to weakness of the diaphragm and accessory muscles, and centrally mediated respiratory involvement has also been described. Patients should be referred to a pulmonologist for assessment, and symptoms of hypoventilation, such as morning headaches and progressive daytime fatigue, should be specifically addressed at an annual check-up. Many patients need assisted ventilation at night. Even after successful treatment of nocturnal hypoventilation, some patients will still experience significant daytime fatigue, which may be centrally mediated.

Caution in relation to surgery and anaesthesia

Critical information about the condition should be entered in the summary care record for all patients with myotonic dystrophy type 1, and respiration and cardiac function should be assessed before surgery. Patients may have myotonia in the tongue/jaw, which can complicate intubation. They also have increased sensitivity to muscle relaxant medications, and depolarising muscle relaxants in particular should be avoided. Inhalation anaesthesia should be used with caution in patients with cardiomyopathy (18). Patients require close monitoring after anaesthesia, and a prolonged awakening time must be expected. Chronic respiratory failure is common in myotonic dystrophy type 1. If oxygen supplementation is needed, the patient must be monitored, and caution must be exercised as this can lead to CO₂ retention. A pulmonologist should be involved. Local anaesthetic and nitrous oxide are safe for minor procedures.

Endocrinology

Adult patients have an increased risk of type 2 diabetes mellitus, hypothyroidism and infertility. Monitoring of HbA1c and thyroid function tests are recommended annually for adults (4) and every three years or upon clinical suspicion for children (3).

Cognitive involvement

The cognitive profile varies from extensive impairment indicative of intellectual disability to few or no symptoms or findings. Impairment can manifest from early childhood but may not present until adulthood. Milder impairment is generally observed in individuals with a late onset phenotype, while those with onset in early childhood experience more severe symptoms. However, patients with a late onset phenotype can sometimes exhibit a relatively rapid decline in certain cognitive functions (4). Patients may have problems with memory, spatial and directional orientation, and concentration. Challenges with executive functions can also be seen, such as planning, abstract thinking, mental flexibility and impulse control (19). This often manifests as a lack of motivation and apathy, and many require considerable help to perform daily activities. Both research and clinical experience indicate that cognitive problems have a major impact on the quality of life of individuals facing such challenges (3).

Milder cognitive outcomes, such as executive function impairment, can also lead to difficulties in functioning in everyday life. There should be a low threshold for performing a neuropsychological investigation. A structured assessment of neuropsychological function and activities of daily living is a useful tool for patients and family members to better understand and manage the difficulties. Many people with myotonic dystrophy type 1 and cognitive problems have poor insight into their illness. This can lead to difficulties for healthcare personnel in obtaining accurate anamnestic information and to a lack of appointment follow-up and adherence to interventions. Regardless of why a patient lacks insight into their condition, it is important to recognise that this is not deliberate on their part. Family members and support services should be actively involved in the ongoing care and support, and it is recommended that patients have someone accompany them to medical appointments.

Other symptoms and findings

Cataracts with an unknown aetiology are a key warning symptom and often the only finding in those with late adult-onset myotonic dystrophy type 1 (4, 8, 20). In a Norwegian study of 50 adult patients, 84 % respondents reported chronic

pain (21). Many struggle with diarrhoea or constipation and abdominal pain, which can lead to pseudo-obstruction and repeated hospitalisation (22). A considerable proportion also experience urinary incontinence (22). Myotonic dystrophy type 1 also increases the risk of cancer, but there are so far no specific screening programmes (23).

Follow-up and treatment

There is no specific medication for myotonic dystrophy type 1, but trials are underway, including gene-modifying therapies such as antisense oligonucleotides (24).

Myotonic dystrophy type 1 is progressive, and regular follow-up in both the primary and specialist healthcare services is therefore crucial. Specific monitoring of the heart and respiratory system as described above is recommended. In cases of significant impairment and onset in childhood, patients should receive follow-up from the habilitation service. Many adult patients can benefit from in-patient rehabilitation. Physical activity and strength training are recommended to prevent deconditioning of unaffected muscles, preferably under the guidance of a physiotherapist familiar with the diagnosis. In cases of cardiac involvement, aerobic exercise should be carried out in consultation with a cardiologist.

Which type of strength training is effective is the subject of ongoing research. Cognitive therapy, in combination with an exercise programme where appropriate, has also been shown to be effective in reducing fatigue in this patient group (25). Affected patients, and parents of paediatric patients, should receive genetic counselling once the diagnosis is confirmed. It is important that the child is offered this again when they reach adulthood. Patients and family members in Norway can be advised to join the Muscular Dystrophy Association (*Foreningen for Muskelsyke*). The association also has a separate youth group.

Myotonic dystrophy type 1 presents challenges for healthy family members of a patient. In many families, the disease only comes to light when a severely affected child is born, but then several family members are often found to have the diagnosis, such as one of the parents of the child. Where the child experiences social challenges at school and a spouse with the diagnosis lacks motivation, experiences fatigue, and has a limited capacity to contribute, it places a particularly heavy burden on the healthy partner in the relationship. The Unit for Congenital and Inherited Neuromuscular Disorders at Oslo University Hospital has produced a handbook for family members of adult patients with myotonic dystrophy type 1 (26). This can be useful both for family members and for patients when dealing with support services.

The article has been peer-reviewed.

REFERENCES

1. Liao Q, Zhang Y, He J et al. Global Prevalence of Myotonic Dystrophy: An Updated Systematic Review and Meta-Analysis. *Neuroepidemiology* 2022; 56: 163–73. [PubMed][CrossRef]
2. Müller KI, Ghelue MV, Lund I et al. The prevalence of hereditary neuromuscular disorders in Northern Norway. *Brain Behav* 2021; 11. doi: 10.1002/brb3.1948. [PubMed][CrossRef]
3. Johnson NE, Aldana EZ, Angeard N et al. Consensus-based care recommendations for congenital and childhood-onset myotonic dystrophy type 1. *Neurol Clin Pract* 2019; 9: 443–54. [PubMed][CrossRef]
4. Ashizawa T, Gagnon C, Groh WJ et al. Consensus-based care recommendations for adults with myotonic dystrophy type 1. *Neurol Clin Pract* 2018; 8: 507–20. [PubMed][CrossRef]
5. Bird TD. Myotonic Dystrophy Type 1. I: Adam MP, Feldman J, Mirzaa GM et al., red. Seattle, WA: GeneReviews, 1993.
6. Buxton J, Shelbourne P, Davies J et al. Detection of an unstable fragment of DNA specific to individuals with myotonic dystrophy. *Nature* 1992; 355: 547–8. [PubMed][CrossRef]
7. Winblad S, Samuelsson L, Lindberg C et al. Cognition in myotonic dystrophy type 1: a 5-year follow-up study. *Eur J Neurol* 2016; 23: 1471–6. [PubMed][CrossRef]
8. Hamel JI. Myotonic Dystrophy. *Continuum (Minneap Minn)* 2022; 28: 1715–34. [PubMed][CrossRef]
9. Aden P, Skarbø AB, Wallace S et al. Cognitive function, behaviour and quality of life in children with myotonic dystrophy type 1 in South - Eastern Norway. *Eur J Paediatr Neurol* 2023; 45: 1–6. [PubMed][CrossRef]
10. Lagrue E, Dogan C, De Antonio M et al. A large multicenter study of pediatric myotonic dystrophy type 1 for evidence-based management. *Neurology* 2019; 92: e852–65. [PubMed][CrossRef]
11. Joosten IBT, Horlings CGC, Vosse BAH et al. Myotonic dystrophy type 1: A comparison between the adult- and late-onset subtype. *Muscle Nerve* 2023; 67: 130–7. [PubMed][CrossRef]
12. Hilbert JE, Ashizawa T, Day JW et al. Diagnostic odyssey of patients with myotonic dystrophy. *J Neurol* 2013; 260: 2497–504. [PubMed][CrossRef]
13. Solbakken G, Ørstavik K, Hagen T et al. Major involvement of trunk muscles in myotonic dystrophy type 1. *Acta Neurol Scand* 2016; 134: 467–73. [PubMed][CrossRef]
14. Turner C, Hilton-Jones D. Myotonic dystrophy: diagnosis, management and new therapies. *Curr Opin Neurol* 2014; 27: 599–606. [PubMed]

[CrossRef]

15. Petri H, Vissing J, Witting N et al. Cardiac manifestations of myotonic dystrophy type 1. *Int J Cardiol* 2012; 160: 82–8. [PubMed][CrossRef]
16. Hasselberg NE, Berge KE, Rasmussen M et al. Kardiomyopati ved arvelig skjelettmuskeldystrofi. *Tidsskr Nor Legeforen* 2018; 138. doi: 10.4045/tidsskr.16.0683. [PubMed][CrossRef]
17. Hawkins AM, Hawkins CL, Abdul Razak K et al. Respiratory dysfunction in myotonic dystrophy type 1: A systematic review. *Neuromuscul Disord* 2019; 29: 198–212. [PubMed][CrossRef]
18. Ferschl M, Moxley R, Day JW et al. Practical suggestions for the anesthetic management of a myotonic dystrophy patient. https://www.myotonic.org/sites/default/files/MDF_LongForm_AnesGuidelines_01C.pdf Accessed 29.1.2024.
19. Morin A, Funkiewiez A, Routier A et al. Unravelling the impact of frontal lobe impairment for social dysfunction in myotonic dystrophy type 1. *Brain Commun* 2022; 4. doi: 10.1093/braincomms/fcac111. [PubMed][CrossRef]
20. Boonstra NE, Varhaug KN. Øyesykdom ved dystrophia myotonica type 1. *Tidsskr Nor Legeforen* 2023; 143. doi: 10.4045/tidsskr.22.0608. [PubMed][CrossRef]
21. Solbakken G, Løseth S, Froholdt A et al. Pain in adult myotonic dystrophy type 1: relation to function and gender. *BMC Neurol* 2021; 21: 101. [PubMed][CrossRef]
22. Fisette-Paulhus I, Gagnon C, Girard-Côté L et al. Genitourinary and lower gastrointestinal conditions in patients with myotonic dystrophy type 1: A systematic review of evidence and implications for clinical practice. *Neuromuscul Disord* 2022; 32: 361–76. [PubMed][CrossRef]
23. D'Ambrosio ES, Gonzalez-Perez P. Cancer and Myotonic Dystrophy. *J Clin Med* 2023; 12: 1939. [PubMed][CrossRef]
24. De Serres-Bérard T, Ait Benichou S, Jauvin D et al. Recent Progress and Challenges in the Development of Antisense Therapies for Myotonic Dystrophy Type 1. *Int J Mol Sci* 2022; 23: 13359. [PubMed][CrossRef]
25. OPTIMISTIC consortium. Cognitive behavioural therapy with optional graded exercise therapy in patients with severe fatigue with myotonic dystrophy type 1: a multicentre, single-blind, randomised trial. *Lancet Neurol* 2018; 17: 671–80. [PubMed][CrossRef]
26. Enhet for medfødte og arvelige nevromuskulære tilstander, Oslo Universitetssykehus. Informasjonsperm om dystrofia myotonika type 1. <https://ffm.no/wp-content/uploads/2022/11/Informasjonsperm-DM1.pdf> Accessed 20.1.2024.

Publisert: 23 April 2024. Tidsskr Nor Legeforen. DOI: 10.4045/tidsskr.23.0687
Received 11.10.2023, first revision submitted 29.1.2024, accepted 16.2.2024.
Published under open access CC BY-ND. Downloaded from tidsskriftet.no 24 June 2026.