

---

# Medication error with methotrexate

---

## SHORT CASE REPORT

MAREN WENNBORG HUSBY

[maren.w.h@hotmail.com](mailto:maren.w.h@hotmail.com)

Clinic of Emergency Medicine and Prehospital Care  
St Olav's Hospital, Trondheim University Hospital  
and

Medical University of Warsaw

Maren Wennberg Husby, 6th year medical student in Warsaw, Poland,  
and licensed medical student at St Olav's Hospital, Trondheim  
University Hospital.

The author has completed the ICMJE form and declares no conflicts of  
interest.

LARS PETTER BACHE-WIIG BJØRNSEN

Clinic of Emergency Medicine and Prehospital Care  
St Olav's Hospital, Trondheim University Hospital and  
Department of Circulation and Medical Imaging

Norwegian University of Science and Technology (NTNU)

Lars Petter Bache-Wiig Bjørnsen, PhD, specialist in emergency medicine  
and prehospital care, senior consultant and associate professor.

The author has completed the ICMJE form and declares no conflicts of  
interest.

ARVE JØRGENSEN

Department of Circulation and Medical Imaging  
Norwegian University of Science and Technology (NTNU)  
and

Department of Radiology and Nuclear Medicine  
St Olav's Hospital, Trondheim University Hospital

Arve Jørgensen, PhD, specialist in radiology, associate professor and  
senior consultant.

The author has completed the ICMJE form and declares no conflicts of  
interest.

STONE MERETE LASSEN

Clinic of Emergency Medicine and Prehospital Care  
St Olav's Hospital, Trondheim University Hospital  
Tone Merete Lassen, pharmacist.

The author has completed the ICMJE form and declares no conflicts of interest.

DAG JACOBSEN

Accident and Emergency Department  
Oslo University Hospital, Ullevål  
and  
Norwegian Poisons Information Centre  
Norwegian Institute of Public Health  
and  
Institute of Clinical Medicine  
University of Oslo

Dag Jacobsen, toxicologist (NAVF), specialist in clinical pharmacology, internal medicine and cardiology. He is a senior consultant, professor emeritus and clinical secondary on-call doctor at the Norwegian Poisons Information Centre.

The author has completed the ICMJE form and declares no conflicts of interest.

LARS ERIK LAUGSAND

Clinic of Emergency Medicine and Prehospital Care  
St Olav's Hospital, Trondheim University Hospital and  
Department of Circulation and Medical Imaging  
Norwegian University of Science and Technology (NTNU)  
Lars Erik Laugsand, PhD, specialist in emergency medicine and prehospital care, senior consultant and associate professor.

The author has completed the ICMJE form and declares no conflicts of interest.

---

## Background

A woman in her seventies presented to the accident and emergency department (A&E) with shortness of breath that had increased over a period of three weeks. She had a history of COPD, hypertension and polymyalgia rheumatica. A medication error involving methotrexate, used for autoimmune diseases, was discovered during her medical history review.

## Case presentation

The patient arrived with stable vital signs, including 94 % oxygen saturation and a respiratory rate of 20 breaths/min. She had been taking 2.5 mg of methotrexate daily for the past three weeks instead of the prescribed weekly dose of 15 mg. Other examinations revealed no alarming findings, except for a slightly elevated D-dimer level.

## Interpretation

Considering her medical history and exclusion of other differential diagnoses, methotrexate toxicity was suspected. The patient was admitted to the hospital and intravenous folinic acid was initiated as an antidote treatment. Five days later, the patient was discharged with an improvement in the shortness of breath. This case underscores the importance of effective communication in health care, particularly in complex cases like this, where understanding dosages and administration is crucial. Medical history, clinical examinations and medication reviews, often involving clinical pharmacists, are vital in the A&E to reveal medication errors.

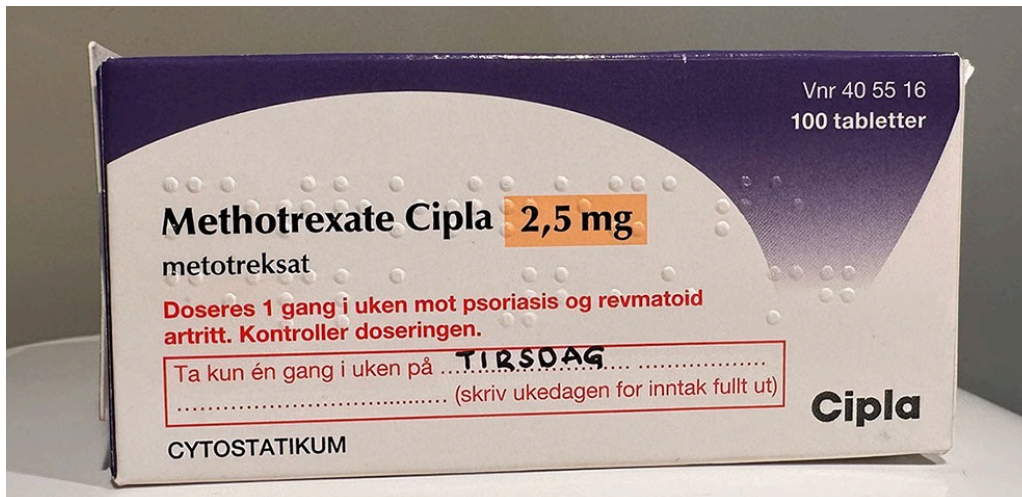
---

## **An older woman was referred to the accident and emergency department due to increasing shortness of breath over the preceding three weeks. Her problems were caused by incorrect administration of methotrexate.**

A woman in her seventies with diagnosed chronic obstructive pulmonary disease (COPD), hypertension and polymyalgia rheumatica was referred to the accident and emergency department (A&E) due to increasing functional dyspnoea and respiratory-dependent chest pain over the preceding three weeks. She was afebrile with blood pressure of 122/78 mmHg, regular pulse of 78 beats per minute and respiratory rate of 20 breaths per minute. The chest pain was not aggravated by exertion. She did not have speaking-related dyspnoea, cyanosis, cough or expectoration, and did not use respiratory accessory muscles, but experienced shortness of breath when undressing.

Bilateral basal crepitation was found in the lungs as well as palpation tenderness in the intercostal muscles. The lower extremities were slender and exhibited good circulation. Oxygen saturation in room air was 94 %, arterial blood gas showed hypoxemia with  $P_{aO_2}$  8.7 kPa (reference range 11–14) and normal  $p_aCO_2$ . Haemoglobin was 13.3 g/dL (11.7–15.3), leukocytes  $7.3 \times 10^9/L$  ( $4.1\text{--}9.8 \times 10^9/L$ ), platelets  $246 \times 10^9/L$  ( $164\text{--}370 \times 10^9/L$ ) and CRP 51 mg/L ( $< 5$ ). ECG findings were normal. Troponin-T was 15 ng/L ( $< 14$ ) and proBNP 53 ng/L ( $< 738$ ). Nasopharyngeal swabs were negative for SARS-CoV-2, influenza and respiratory syncytial virus (RSV). Chest X-rays and an exploratory ultrasound examination of the heart showed normal findings. D-dimer was 0.82 mg/L FEU ( $< 0.50$ ), but CT angiography showed no pulmonary embolism.

A medication review by a doctor and pharmacist revealed that five months prior, the patient had been prescribed four methotrexate tablets 2.5 mg once a week for polymyalgia rheumatica. Over the course of three months, the weekly dose was supposed to be increased to six tablets – on the same day of the week. The patient was independent and administered the medication correctly until three weeks before admission, when she started taking one 2.5 mg methotrexate tablet daily, despite both the prescription and the medication packaging clearly stating that the medication should only be taken once a week (Figure 1).



**Figure 1** Medication packaging for methotrexate. Note the red highlighted text to emphasise that the medicine should only be taken once a week. Photo: Maren Wennberg Husby

The serum concentration of methotrexate upon admission was 0.04  $\mu\text{mol/L}$ . Following recommendation by the Norwegian Poisons Information Centre, she received 50 mg of intravenous folic acid antidote treatment four times daily for four days. There were no signs of bone marrow suppression, and in subsequent checks, the serum concentration was  $< 0.04 \mu\text{mol/L}$ , rendering further antidote treatment unnecessary. Chest CT showed a moderate degree of centrilobular emphysema and chronic bronchial changes, which were previously known and are typical in patients with COPD.

No findings relating to methotrexate poisoning, such as consolidation, ground-glass changes, reticular opacities and centrilobular nodules, were detected (1). The patient's breathing gradually improved and she was discharged on day 5 with 45 mg folic acid tablets three times daily for three days. In the discharge summary, the patient's general practitioner (GP) was advised to measure haemoglobin, neutrophil granulocytes and platelets three days after discharge in order to test for possible bone marrow suppression, and to consider assistance with medication management.

---

## Discussion

Methotrexate in low doses (7.5–30 mg/week) is used to treat autoimmune diseases such as rheumatoid arthritis and psoriasis (2). In 2014, this medicine was used by around 25 000 patients in Norway (3). Methotrexate is an

antimetabolite that inhibits dihydrofolate reductase, thereby limiting the conversion of folic acid to tetrahydrofolate, which is necessary for DNA synthesis and cell proliferation (4). This leads to cell death, especially in tissues with rapid cell division, such as bone marrow, skin and mucous membranes (5).

The toxicity of methotrexate depends on the dose, duration of exposure and risk factors (6). A narrow therapeutic window means that a toxic level is quickly reached with repeated doses. To minimise toxicity, methotrexate should only be taken once a week, with folic acid taken on the remaining days of the week. Single doses saturate absorption, which results in reduced bioavailability and toxicity of the antimetabolite (5). Incorrect dosing can have serious consequences, including death. A daily intake of just 2.5 mg for three days or more is considered potentially serious. We therefore decided to initiate antidote treatment as quickly as possible. Serious adverse effects, such as bone marrow suppression and sepsis, typically manifest within 2–3 weeks.

Reduced kidney function is the most significant factor predisposing to adverse effects. Other factors include age over 75 years, ongoing infection, liver failure, malnutrition and hypoalbuminaemia (5). Methotrexate-induced pneumonitis can occur regardless of dosage. Symptoms can range from mild dyspnoea to fatal respiratory failure (4). In cases of new-onset respiratory symptoms during methotrexate treatment, there should be a low threshold for assessing for pneumonitis.

In 2015, Norway's largest provider of health-related information, *Norsk helseinformatikk*, wrote that methotrexate could be linked to 20 deaths over the last decade (3). The Norwegian Medical Products Agency therefore demanded improvements to the labelling of medication packaging. The packaging states that the medicine should only be taken as a single weekly dose. The Norwegian Rheumatology Association has produced patient information stating that 'Methotrexate is only to be taken one day per week. Daily use will entail a significant risk of serious adverse effects' (7). The patient had received written and oral instruction on the use of methotrexate. There were no recent changes in dose, packaging or interactions with healthcare personnel that could explain the patient's change in dosage.

Challenges with medication management and recalling events were observed in the patient during hospitalisation and after discharge. We have concluded that the dosing error in this case could be attributed to cognitive impairment. When prescribing methotrexate, the prescribing doctor must inform the patient about the consequences of daily administration and also ensure that proper medication management is maintained. This includes assessing cognitive status. At St Olav's Hospital in Trondheim, pharmacists are stationed in A&E to perform medication reconciliation early in the patient pathway, using the standardised Integrated Medicines Management (IMM) method (8).

Methotrexate is a cytotoxic medication intended to be taken once a week. Incorrect administration can lead to serious consequences, including death. The prescribing doctor must ensure that proper medication management is

maintained by the patient or the person administering the medication. This involves providing detailed information on how the medication must only be taken once a week, and assessing cognitive status.

---

*The patient has consented to publication of this article.*

*The article has been peer-reviewed.*

---

## REFERENCES

1. Sridhar S, Kanne JP, Henry TS et al. Medication-induced Pulmonary Injury: A Scenario- and Pattern-based Approach to a Perplexing Problem. *Radiographics* 2022; 42: 38–55. [PubMed][CrossRef]
  2. Schicchi A, Scaravaggi G, Petrolini VM et al. Poisoning related to therapeutic error in prolonged low-dose methotrexate treatment. *Br J Clin Pharmacol* 2021; 87: 2385–91. [PubMed][CrossRef]
  3. Norsk Helseinformatikk. Advarsel mot daglig bruk av metotreksattabletter – bedre merking av emballasje. <https://nhi.no/for-helsepersonell/nytt-om-legemidler/arkiv-lmv-20152016/advarsel-mot-daglig-bruk-av-metotreksattabletter-bedre-merking-av-emballasje/> Accessed 28.8.2023.
  4. Felleskatalogen. Methotrexate. <https://www.felleskatalogen.no/medisin/methotrexate-pfizer-561415/> Accessed 28.8.2023.
  5. Giftinformasjonen. Metotreksat - behandlingsanbefaling ved akutt forgiftning. <https://www.helsebiblioteket.no/forgiftninger/legemidler/metotreksat-behandlingsanbefaling-ved-akutt-forgiftning> Accessed 28.8.2023.
  6. Giftinformasjonen. Metotreksat - behandlingsanbefaling for feildoseringer ved lavdosebehandling. <https://www.helsebiblioteket.no/forgiftninger/legemidler/metotreksat-behandlingsanbefaling-for-feildoseringer-ved-lavdosebehandling/> Accessed 28.8.2023.
  7. Norsk revmatologisk forening. Metotreksat. <https://www.legeforeningen.no/foreningsledd/fagmed/Norsk-revmatologisk-forening/pasientinformasjon/medikamenter/metotrexat/> Accessed 21.12.2023.
  8. Major ALS. IMM-modellen til Norge. *Nor Farm Tidsskr* 2012; 120: 12–4.
- 

Publisert: 21 March 2024. *Tidsskr Nor Legeforen*. DOI: 10.4045/tidsskr.23.0657

Received 1.10.2023, first revision submitted 2.1.2024, accepted 9.2.2024.

Published under open access CC BY-ND. Downloaded from [tidsskriftet.no](http://tidsskriftet.no) 23 June 2026.