
Narrow angle between superior mesenteric artery and aorta

IMAGES IN MEDICINE

JØRGEN VALEUR

jorgen.valeur@lds.no

Lovisenberg Diaconal Hospital

and

Institute of Clinical Medicine

University of Oslo

Jørgen Valeur, specialist in internal medicine and gastrointestinal disorders, senior consultant and professor.

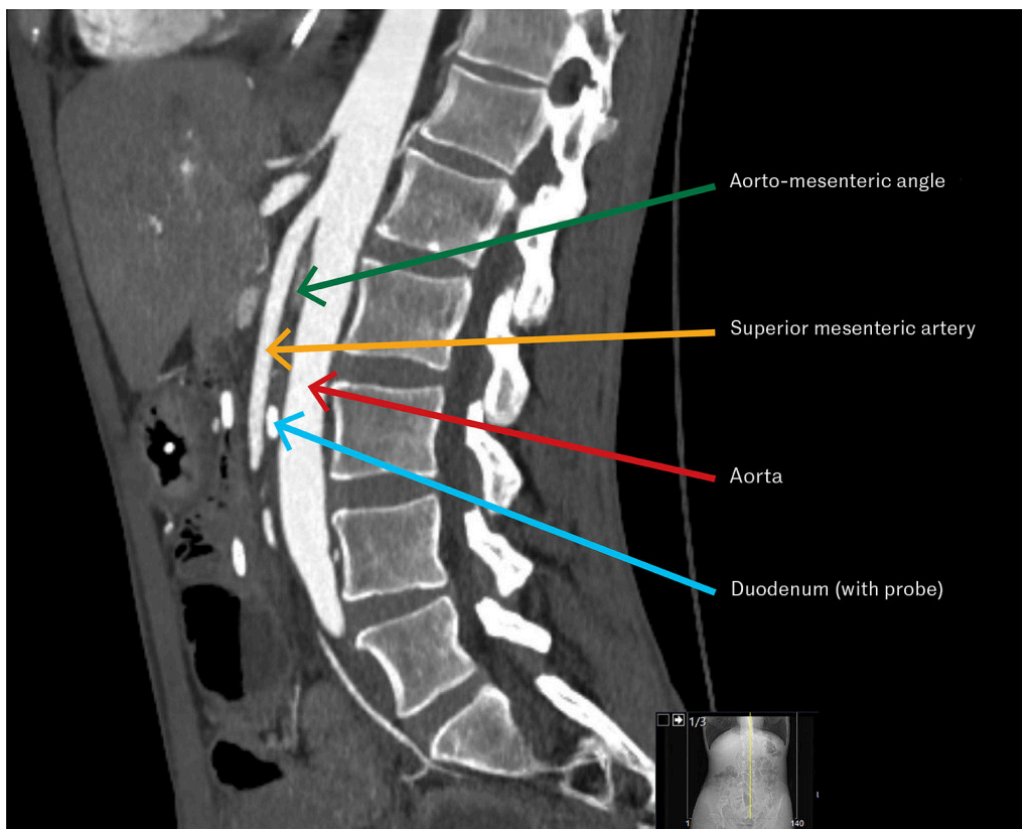
The author has completed the ICMJE form and declares no conflicts of interest.

ANDREAS LYKKE RICKERS

Lovisenberg Diaconal Hospital

Andreas Lykke Rickers, specialist in radiology and senior consultant.

The author has completed the ICMJE form and declares no conflicts of interest.



The CT image shows a sagittal section of the abdomen revealing a narrow angle between the superior mesenteric artery and abdominal aorta, which, along with symptoms and endoscopic findings, led to the diagnosis of superior mesenteric artery syndrome.

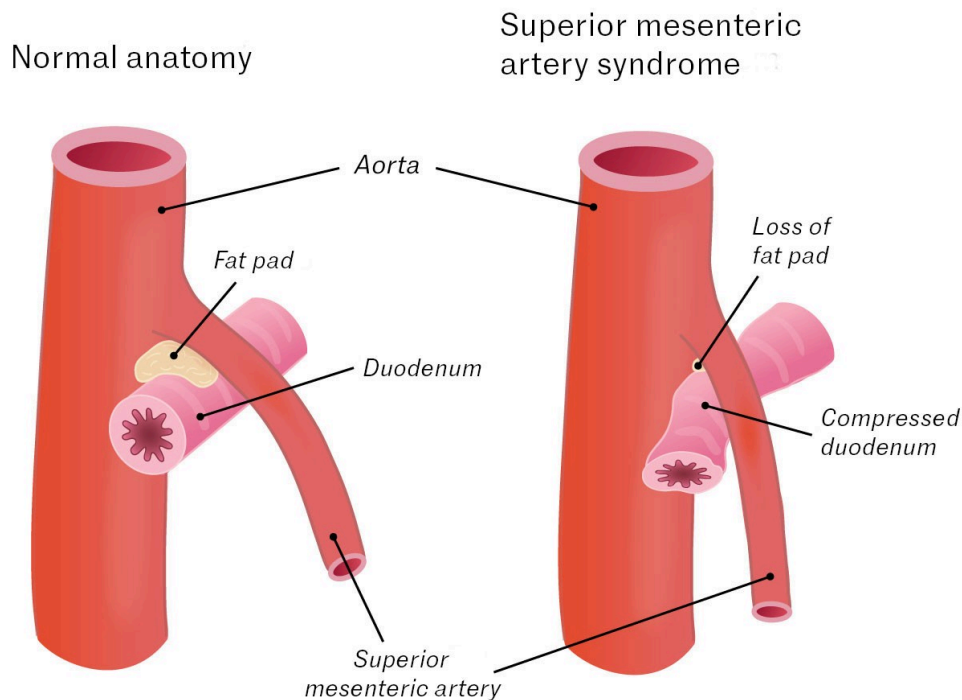
A woman in her forties with known anorexia nervosa was admitted for investigation of postprandial epigastric pain, satiety, nausea and constipation. These symptoms had developed over the two years prior to admission. Her body mass index was 14.6 kg/m².

Colonoscopy revealed aphthous ulceration of unknown aetiology in the terminal ileum. MRI findings in the small intestine were normal. After these examinations, the epigastric pain intensified, and the patient vomited several times. Gastroscopy showed oesophagitis and significant amounts of content in the ventricle. The patient was treated with pantoprazole (80 mg × 2 intravenously) to inhibit gastric acid production and metoclopramide (10 mg × 3 intravenously) to stimulate gastric motility.

A new gastroscopy after three days showed no content in the ventricle and complete resolution of the oesophagitis changes. No outlet obstruction for the ventricle was observed, and findings for the duodenum were normal. As the patient had experienced gastric retention and could not tolerate food in the stomach, a nasojejunal tube was inserted.

Based on the patient's symptoms and the gastroscopic finding of gastric retention, superior mesenteric artery syndrome was suspected (see illustration). CT angiography of the abdominal vessels showed an angle between the aorta and the origin of the superior mesenteric artery of 18 degrees

(normal is > 25 degrees), and the aortomesenteric distance at the level of the duodenum was 5 mm (normal is > 10 mm). The findings were consistent with the diagnosis [\(1\)](#).



The distal duodenum is situated between the aorta and the superior mesenteric artery. If the angle between the aorta and the superior mesenteric artery becomes too acute, it can lead to compression of the distal duodenum. This in turn can lead to gastric retention, resulting in symptoms from the upper part of the stomach, such as pain, bloating and vomiting. Emaciation with loss of adipose tissue in the aortomesenteric space is the most common cause. The primary treatment is intensive nutritional therapy, with the goal of rebuilding the 'fat pad' to increase the angle and facilitate passage through the duodenum. Surgery is recommended if therapy fails [\(1\)](#).

Superior mesenteric artery syndrome is rare, with an estimated incidence in the general population of 0.013–0.78 % [\(1\)](#). Patients with unexplained gastric retention in connection with weight loss should be examined for the syndrome. Healthcare personnel who treat patients with eating disorders must be particularly vigilant.

The patient has consented to publication of this article.

The article has been peer-reviewed.

REFERENCES

1. Oka A, Awoniyi M, Hasegawa N et al. Superior mesenteric artery syndrome: Diagnosis and management. *World J Clin Cases* 2023; 11: 3369–84. [PubMed][CrossRef]

Publisert: 7 February 2024. Tidsskr Nor Legeforen. DOI: 10.4045/tidsskr.23.0756

Received 3.11.2023, first revision submitted 6.12.2023, accepted 11.12.2023.
Copyright: © Tidsskriftet 2026 Downloaded from tidsskriftet.no 19 June 2026.