
Ectropion

CLINICAL REVIEW

AYYAD ZARTASHT KHAN

ayyad.ahmad.zartasht.khan@nordlandssykehuset.no

Department of Ophthalmology

Nordland Hospital

Author contribution: concept, draft and revision of the manuscript, and approval of the submitted version.

Ayyad Zartasht Khan, PhD, specialty registrar in ophthalmology.

The author has completed the ICMJE form and declares the following conflicts of interest: he has ownership interests in the Eye Health Clinic and Dry Eye Clinic, which offer oculoplastic surgery, and gives lectures for and/or receives financial support from Abigo, Alcon, Allergan, AMWO, Bausch & Lomb, Bayer, European School for Advanced Studies in Ophthalmology, Innz Medical, Medilens Nordic, Medistim, Novartis, Santen, Specsavers, Shire Pharmaceuticals and Théa Laboratories.

HANS OLAV UELAND

Department of Ophthalmology

Haukeland University Hospital

Author contribution: draft and revision of the manuscript, and approval of the submitted version.

Hans Olav Ueland, PhD in oculoplastic surgery, specialist in ophthalmology, senior consultant and postdoctoral fellow.

The author has completed the ICMJE form and declares the following conflicts of interest: he holds a 50 % postdoctoral position funded by Western Norway Regional Health Authority among others and is the lead in a multi-centre study funded by Klinbeforsk and the Norwegian Thyroid Association (*Stoffskifteforbundet*). The drugs in this study are paid for by Pfizer. He has received travel and accommodation expenses from Novartis and Allergan for two conferences in the field of medical retina.

ELIN BOHMAN

Department of Clinical Neuroscience
Division of Eye and Vision Karolinska Institutet
and
Section for Eye, Tear Duct and Orbital Surgery
St Erik Eye Hospital

Author contribution: draft and revision of the manuscript, and approval of the submitted version.

Elin Bohman, PhD in oculoplastics, specialist in ophthalmology, head of section (St Erik Eye Hospital).

The author has completed the ICMJE form and declares the following conflict of interest: she has received lecture fees from Santen.

KIM ALEXANDER TØNSETH

Division of Plastic and Reconstructive Surgery
Oslo University Hospital
and
Institute of Clinical Medicine
University of Oslo

Author contribution: draft and revision of the manuscript, and approval of the submitted version.

Kim Alexander Tønseth, specialist in plastic surgery, head of division and professor.

The author has completed the ICMJE form and declares no conflicts of interest.

TOR PAASKE UTHEIM

Department of Ophthalmology
Drammen Hospital
and

Department of Ophthalmology
Oslo University Hospital
and

Department of Ophthalmology
Stavanger University Hospital
and

Department of Ophthalmology
Sørlandet Hospital, Arendal
and

Department of Ophthalmology Vestfold Hospital, Tønsberg
and

Division of Plastic and Reconstructive Surgery
Department of Maxillofacial Surgery
Department of Medical Biochemistry
Oslo University Hospital

Tor Paaske Utheim, specialist in ophthalmology, head of research and innovation, and professor.

Author contribution: concept, draft and revision of the manuscript, and approval of the submitted version.

In ectropion, the eyelid margin – typically the lower eyelid – is turned outward. This condition is becoming increasingly common due to the ageing population. Ectropion is classified as either acquired or congenital, with the former being the most prevalent. Acquired ectropion is further divided into involucional, paralytic, mechanical and cicatricial subtypes. Involutional ectropion is the most common where there is no patient population bias. This clinical review provides an overview of ectropion.

The author has completed the ICMJE form and declares the following conflicts of interest: he has ownership interests in the Eye Health Clinic and Dry Eye Clinic, which offer oculoplastic surgery, and gives lectures for and/or receives financial support from Abigo, Alcon, Allergan, AMWO, Bausch & Lomb, Bayer, European School for Advanced Studies in Ophthalmology, Innz Medical, Medilens Nordic, Medistim, Novartis, Santen, Specsavers, Shire Pharmaceuticals and Théa Laboratories.

Ectropion is a condition where the eyelid margin, typically the lower eyelid, turns outward [\(1\)](#). Symptoms include epiphora, eye irritation and foreign body sensation [\(2\)](#). Untreated ectropion can lead to chronic conjunctivitis and secondary eczematous skin changes. In the most severe cases, corneal dryness can cause keratitis and corneal ulcers [\(2, 3\)](#).

Age is the primary risk factor for the development of ectropion [\(4\)](#), and the prevalence increases with age. It has been reported that 1 % of people aged 60–69 years have ectropion, which increases to 7 % for ages 70–79 years and up to 17 % among those aged 80 and over [\(5\)](#). The prevalence is higher in men than women [\(5\)](#). Other risk factors include a history of eyelid trauma, previous eyelid surgery, long-term use of certain eye drops, and skin conditions involving the eyelid. Repeated manipulation of the eyelids over time, such as with contact lens use, also increases the risk of ectropion.

Ectropion is classified as either acquired or congenital, with the former being the most prevalent [\(2\)](#). Acquired ectropion is further divided into involucional (age-related), paralytic, mechanical and cicatricial (scar-related) subtypes. This clinical review provides an overview of the condition and is based on a selective review of the literature and the authors' experiences in clinical practice.

Congenital ectropion

Congenital ectropion is rare and, unlike acquired ectropion, affects the upper eyelid or both the upper and lower eyelids at the same time. The aetiology of the congenital form can vary, and includes ichthyosis, which is a generic term for a group of rare skin conditions resulting from disturbed keratinisation [\(6\)](#) and a missing/atrophied tarsal plate [\(7\)](#). Congenital bilateral upper ectropion is associated with Down syndrome [\(7, 8\)](#). In Norway, patients with congenital ectropion should be referred to the National Service for the Reconstruction of Congenital Malformations in the Eye Region, Department of Ophthalmology, Oslo University Hospital.

Acquired ectropion

Age-related (involutional) acquired ectropion typically presents with bilateral involvement. This is the most common subtype of ectropion and is due to age-related changes in the elastic and collagen fibres of the skin and connective tissue. These changes lead to a loss of skin tightness, weakening of the attachment points of the orbicularis muscle, and loosening of the lateral canthal tendon (tissue strands that attach the eyelids to the lateral orbital rim) (Figure 1). The result is eyelid eversion.

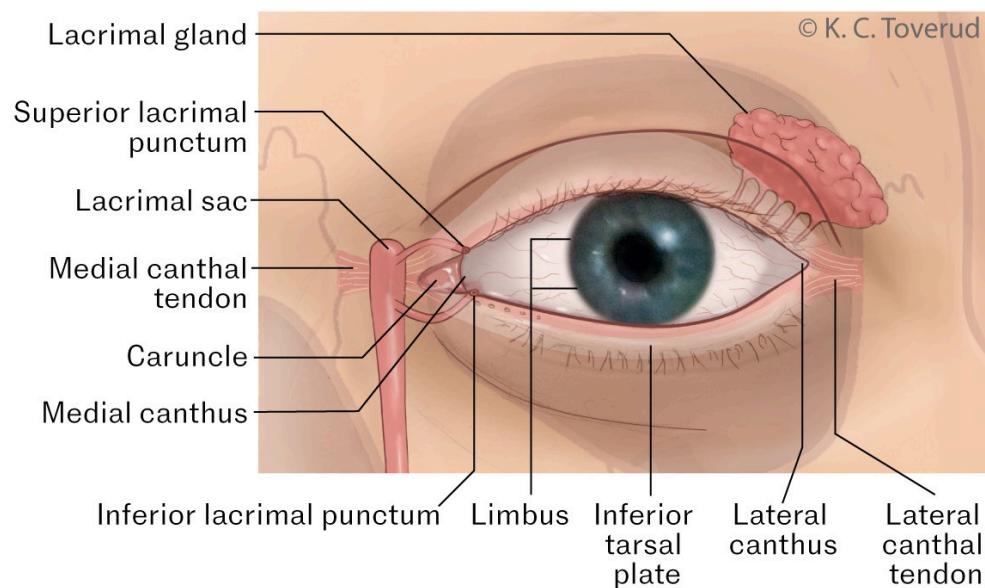


Figure 1 Eye/eyelid anatomy. Illustration of the various anatomical structures that are or can be involved in ectropion.

Unlike involutional ectropion, paralytic ectropion is normally unilateral. This subtype is caused by peripheral facial nerve palsy. As the orbicularis muscle is innervated by the facial nerve, peripheral facial nerve palsy can lead to ectropion.

Mechanical ectropion, as the name suggests, results from the weight of a mass pulling the lower eyelid down and outwards. Oedema and tumours on the lower eyelid can, due to the gravitational force, exert downward traction on the lower

eyelid, causing it to turn outward.

Cicatricial ectropion is characterised by a shortening/contracture of the anterior lid lamella. Common causes include trauma, burns, certain skin conditions, such as ichthyosis, and certain eye drops, such as dorzolamide (9).

Assessment

Thorough preoperative assessment is crucial for correct treatment of ectropion as there is no single surgical approach that is suitable for all patients. In addition to a standard ophthalmological examination, the assessment should also include examinations of the cornea, periorbital anatomy and skin, as well as a simple cranial nerve examination in order to identify any facial nerve palsy that may be causing ectropion. We have also listed additional factors that we believe should be included in an assessment of a patient with ectropion.

Lower eyelid laxity

Normally, the eyelid margin is in contact with the ocular surface. Excessive lower eyelid laxity can cause eyelid eversion. The horizontal laxity of the lower eyelid can be assessed with a test where the lower eyelid is gently pulled forward, and the distance from the eyeball to the lower eyelid is measured (lower lid distraction test). In one study, the mean value for this test in patients with ectropion was around 9 mm (10). However, all such tests must be interpreted in the context of the patient's age, symptoms and other findings that may fit the diagnosis.

Vertical laxity of the lower eyelid can be tested by pulling the lower eyelid downward with a finger and releasing it without the patient blinking (snap-back test). Normally, the eyelid will immediately snap back to its original position close to the eyeball. If the test is positive, the eyelid will be slower to return to its original position or the patient will have to blink the eyelid back into the correct position. This suggests abnormal laxity of the eyelid.

Tightness in the lower eyelid margin

Ectropion is frequently caused by tightness in the skin under the lower eyelid/eyelid margin (due to, for example, scarring). To test this, the lower eyelid is pulled upward, and the extent to which it can be lifted is assessed. Normally, it should be possible to pull the lower eyelid margin at least 2 mm above the limbus. Ectropion caused by abnormal tightness of the skin in the lower eyelid can be corrected with a full-thickness skin graft or flap surgery.

Tear drainage

Ectropion is an outward turning of the entire eyelid margin, or just parts of it. A more medial ectropion can cause misalignment and impairment of the lacrimal punctum, preventing adequate tear drainage. In patients with normal tear production, this can lead to epiphora, but older patients typically do not experience this due to an age-related reduction in tear production.

Diagnostic pitfalls

Attempts should be made to treat and monitor systemic conditions that cause ectropion before considering surgery (11). Certain topical medications such as dorzolamide, brimonidine, erlotinib and tretinoin can induce contact dermatitis and also lead to ectropion (9, 12–16) that persists even after attempted surgical correction (9). For this reason, and because drug-induced ectropion can be reversed by discontinuing the causative medication (12, 14, 17), discontinuation and a short course of glucocorticoid-containing eye drops or a mild glucocorticoid ointment on the eyelid skin should be considered before surgical intervention (9, 13).

Particular attention should be paid to the skin in and below the lower eyelid to identify expansive processes such as squamous cell carcinoma and basal cell carcinoma. These can pull on the lower eyelid, causing ectropion, and must be treated before addressing the ectropion. Vigilance is therefore vital during examination to ensure that any tumours are not overlooked. Additionally, ectropion must not be confused with floppy eyelid syndrome, which is characterised by eyelid hyperlaxity and nighttime eversion of the eyelids, causing eye irritation (18).

Treatment

Surgical correction of ectropion must be tailored to the patient's specific situation. For example, patients with epiphora may require a different surgical technique to correct the position of an everted lacrimal punctum than patients with ectropion without involvement of the lacrimal punctum. Likewise, a different technique, such as a full-thickness skin graft, may be needed for patients with contracture of the lower eyelid.

When correcting involutional ectropion, the goal is to restore the balance between the vertical and horizontal forces exerted on the lower eyelid to the greatest extent possible in order to prevent eversion of the eyelid margin (1). In practice, this involves tightening the lower eyelid. The techniques used to correct involutional ectropion include the lateral tarsal strip procedure (Figure 2), medial spindle procedure, Bick's lateral canthoplasty, and/or medial canthoplasty (4, 19). These procedures are generally performed under local anaesthesia. The lateral tarsal strip procedure is the most common surgical technique, as horizontal laxity is the primary mechanism behind ectropion (20). Another simple and widely used method to increase horizontal tension is to shorten the eyelid by means of a full-thickness eyelid resection, known as a pentagon excision (21).

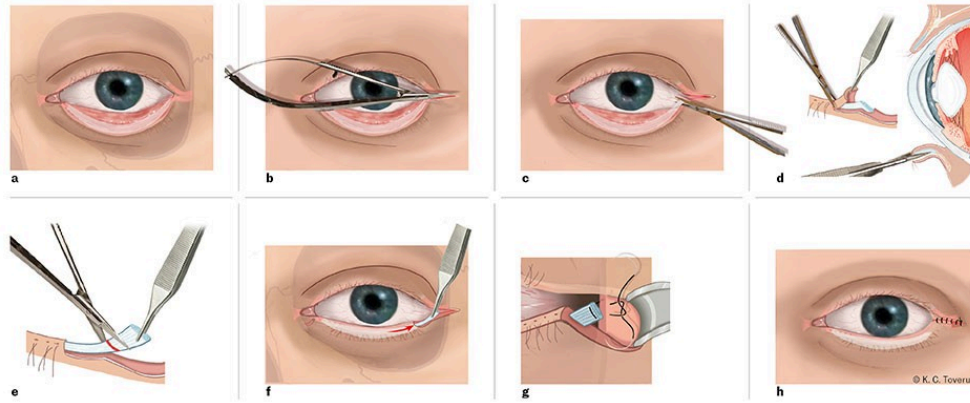


Figure 2 Lateral tarsal strip procedure. Following a canthotomy (b) and cantholysis (c), a small lateral section of the lower tarsal plate is isolated by separating the anterior and posterior lamellae and cutting away the epithelial layer on the eyelid margin of the tarsal segment (d). The conjunctiva is scraped away on the inside of the tarsal segment, and the isolated tarsal segment is cut/shortened as needed (e). The tarsal flap (f) is attached to the periosteum on the lateral orbital rim (g), and the corner of the eye (canthus) is sutured together in multiple layers (h).

Temporary conservative approaches while awaiting surgery include moisturising eye ointment, artificial tear fluid, and/or eyelid taping.

Summary

Ectropion is a condition where the eyelid margin turns outward, and symptoms include epiphora, eye irritation and foreign body sensation. The prevalence increases with age, and men are overrepresented. The condition is mainly due to reduced horizontal tension caused by age-related weakening of the muscles and connective tissue in the eyelid (involutional ectropion). Surgical correction is performed in most cases under local anaesthesia. The most common surgical technique is the lateral tarsal strip procedure, which can also be combined with other techniques. While awaiting treatment, eye ointment and/or eye drops should be used to prevent dryness and damage to the cornea.

The article has been peer-reviewed.

REFERENCES

1. Tyers AG, Collin JRO. Colour Atlas of Ophthalmic Plastic Surgery. 2. utg. Amsterdam: Elsevier Health Sciences, 2001.
2. Ozgur O, Kaufman EJ. Ectropion. Treasure Island, FL: StatPearls Publishing, 2022.
3. Astori IP, Muller MJ, Pegg SP. Cicatricial, postburn ectropion and exposure keratitis. *Burns* 1998; 24: 64–7. [PubMed][CrossRef]
4. Nerad JA. Techniques in Ophthalmic Plastic Surgery: A Personal Tutorial. 2. utg. Amsterdam: Elsevier Health Sciences, 2020.

5. Mitchell P, Hinchcliffe P, Wang JJ et al. Prevalence and associations with ectropion in an older population: the Blue Mountains Eye Study. *Clin Exp Ophthalmol* 2001; 29: 108–10. [PubMed][CrossRef]
6. Cicinelli MV, Dave TV, Madhuri BK et al. Non-surgical management of congenital ichthyosis using hyaluronic acid gel injection. *Eur J Ophthalmol* 2020; 30: NP7–10. [PubMed][CrossRef]
7. Corredor-Osorio R, Tovilla-Pomar JL, Tovilla-Canales JL. Congenital upper eyelids ectropion in Down's syndrome. *GMS Ophthalmol Cases* 2017; 7: Doc03. [PubMed]
8. Suliman S, Michie C. A case of bilateral congenital eublepharon or ectropion. *West Lond Med J* 2010; 2: 37–41.
9. Hegde V, Robinson R, Dean F et al. Drug-induced ectropion: what is best practice? *Ophthalmology* 2007; 114: 362–6. [PubMed][CrossRef]
10. Milbratz-Moré GH, Pauli MP, Lohn CLB et al. Lower Eyelid Distraction Test: New Insights on the Reference Value. *Ophthalm Plast Reconstr Surg* 2019; 35: 574–7. [PubMed][CrossRef]
11. Gracitelli CP, Osaki TH, Valdrighi NY et al. Cicatricial ectropion secondary to psoriatic arthritis. *Case Rep Ophthalmol Med* 2015; 2015. doi: 10.1155/2015/315465. [PubMed][CrossRef]
12. Aristodemou P, Baer R. Reversible cicatricial ectropion precipitated by topical brimonidine eye drops. *Ophthalm Plast Reconstr Surg* 2008; 24: 57–8. [PubMed][CrossRef]
13. Tsui M, Tajirian A. Cicatricial Ectropion With Topical 5% Fluorouracil Cream. *Dermatol Surg* 2016; 42: 1005–6. [PubMed][CrossRef]
14. Brodell LP, Asselin D, Brodell RT. Reversible ectropion after long-term use of topical tretinoin on photodamaged skin. *J Am Acad Dermatol* 1992; 27: 621–2. [PubMed][CrossRef]
15. Salman A, Cerman E, Seekin D et al. Erlotinib induced ectropion following papulopustular rash. *J Dermatol Case Rep* 2015; 9: 46–8. [PubMed][CrossRef]
16. Hurwitz BS. Cicatricial ectropion: a complication of systemic fluorouracil. *Arch Ophthalmol* 1993; 111: 1608–9. [PubMed][CrossRef]
17. Bartley GB. Reversible lower eyelid ectropion associated with dipivefrin. *Am J Ophthalmol* 1991; 111: 650–1. [PubMed][CrossRef]
18. Salinas R, Puig M, Fry CL et al. Floppy eyelid syndrome: A comprehensive review. *Ocul Surf* 2020; 18: 31–9. [PubMed][CrossRef]
19. Dutton J. *Atlas of Oculoplastic and Orbital Surgery*. Riverwoods, IL: Wolters Kluwer Health, 2013.

20. Anderson RL, Gordy DD. The tarsal strip procedure. *Arch Ophthalmol* 1979; 97: 2192–6. [PubMed][CrossRef]

21. Alghoul MS, Kearney AM, Pacella SJ et al. Eyelid Reconstruction. *Plast Reconstr Surg Glob Open* 2019; 7. doi: 10.1097/GOX.0000000000002520. [PubMed][CrossRef]

Publisert: 23 January 2024. *Tidsskr Nor Legeforen*. DOI: 10.4045/tidsskr.23.0309

Received 26.4.2023, first revision submitted 26.9.2023, accepted 13.11.2023.

Published under open access CC BY-ND. Downloaded from *tidsskriftet.no* 27 June 2026.