
Primary progressive aphasia

CLINICAL REVIEW

PETER BEKKHUS-WETTERBERG

peterwetterberg@gmail.com

Department of Geriatric Medicine

Oslo University Hospital

Author contribution: concept and design; literature review; drafting and revision of the manuscript and approval of the submitted version.

Peter Bekkhus-Wetterberg, senior consultant and specialist in geriatric medicine.

The author has completed the ICMJE form and declares no conflicts of interest.

ANNE BRÆKHUS

Department of Geriatric Medicine

and

Department of Neurology

Oslo University Hospital and

Ageing and Health

Author contribution: concept and design, revision of the manuscript and approval of the submitted version.

Anne Brækhus, dr.med., senior consultant and specialist in neurology.

The author has completed the ICMJE form and declares no conflicts of interest.

EBBA GLØERSEN MÜLLER

Department of Radiology and Nuclear Medicine

Oslo University Hospital

Author contribution: literature review, design, revision of the manuscript and approval of the submitted version.

Ebba Gløersen Müller, senior consultant and specialist in nuclear medicine, and PhD student.

The author has completed the ICMJE form and declares no conflicts of interest.

MONICA IRENE NORVIK

Department of Acquired Brain Injury

Statped

and

MultiLing – Center for Multilingualism in Society across the Lifespan

University of Oslo

Author contribution: concept and design, literature review, revision of the manuscript and approval of the submitted version.

Monica Irene Norvik, speech and language therapist with a PhD in clinical linguistics.

The author has completed the ICMJE form and declares the following conflicts of interest: She is head of Norsk logopedlag [*Norwegian Association of Speech and Language Therapists*] (unpaid position).

INGVILD ELISABETH WINSNES

Department of Linguistics and Scandinavian Studies

University of Oslo

Author contribution: concept and design, literature review, revision of the manuscript and approval of the submitted version.

Ingvild Elisabeth Winsnes, speech and language therapist, and PhD student.

The author has completed the ICMJE form and declares the following conflicts of interest: She has a voluntary position (former head/now board member) in Oslo logopedlag [*Oslo Association of Speech and Language Therapists*].

TORGEIR BRUUN WYLLER

Department of Geriatric Medicine

Oslo University Hospital

Author contribution: revision of the manuscript and approval of the submitted version.

Torgeir Bruun Wyller, specialist in internal medicine and geriatric medicine, senior consultant and professor.

The author has completed the ICMJE form and declares no conflicts of interest.

Neurodegenerative dementia may, in rare cases, initially manifest as isolated language impairments in the absence of other cognitive symptoms. These impairments are often somewhat imprecisely referred to as difficulties with 'word finding'. There are several variants of this form of dementia,

each caused by different underlying neuropathologies. Occasionally problems with speech rather than language predominate. Patients may have exclusively language or speech-related symptoms for several years, but eventually all will progress to generalised dementia. This clinical review describes primary progressive aphasia: a collective term for forms of dementia that begin with language impairments.

The term 'primary progressive aphasia' refers to dementia in which the dominant symptom for the first 1–2 years is aphasia. The diagnosis is not used in cases of language impairments that emerge later in the course of dementia. The prevalence of primary progressive aphasia is estimated to be approximately 3–4 per 100,000 individuals, i.e., about the same as amyotrophic lateral sclerosis (1). In a recent registry study (2), the incidence of primary progressive aphasia (all types) was estimated to be 1.14 per 100,000 person-years, compared with 35.7 per 100,000 person-years for typical Alzheimer's dementia.

In an often-cited consensus report, a distinction is made between three variants of primary progressive aphasia: semantic, logopenic and non-fluent/agrammatic (3) (Table 1). Not all cases of the disease fit into these three categories, and a fourth variant has therefore been proposed: mixed primary progressive aphasia (1). The classification system is under continual review. Some authors refer to the semantic variant as 'semantic dementia', whereas others reserve this designation for more extensive disease (4). The non-fluent variant is also referred to as 'progressive non-fluent aphasia' (PNFA). New research techniques, such as those based on imaging methods that reflect the distribution of pathology in the brain, may well suggest alternative subdivisions (5).

Table 1

Characteristics of primary progressive aphasia variants based on functional impairments in different language tests (3).

Variant	Fluency	Naming	Repetition	Comprehension	Grammar
Semantic	Normal	Highly impaired	Normal	Impaired	Relatively normal
Logopenic	Fluent, but speech is interrupted by word-finding difficulties	Impaired	Impaired	Normal	Normal
Non-fluent	Poor	Normal	Reduced fluency	Normal	Poor

The purpose of this article is to provide a brief overview of the different variants of primary progressive aphasia. The article is based on a discretionary selection of recent review and research articles, textbook chapters, and the authors' clinical experience.

Investigating speech and language difficulties

Whenever dementia manifests with speech or language impairments as the only symptom, in the clinical experience of the authors one of three things tends to happen: 1) The patient receives a diagnosis of aphasia, but the aphasia is attributed to stroke. 2) Patients who have Alzheimer's disease with progressive aphasia are misdiagnosed with frontotemporal dementia, as many doctors are aware that language difficulties can be a symptom of this condition. 3) The patient's language difficulties are attributed to 'memory failure', seemingly supported by poor performance on verbal tests.

Contrary to what has previously been assumed, speech and language therapy can have a clear beneficial effect in primary progressive aphasia (6). These patients should therefore be referred to a speech and language therapist with expertise in this condition. We believe that language tests should be included in the assessment of cognitive impairment and that patients with suspected language impairments should be referred to a specialist memory clinic.

Semantic variant

The doctor asks: 'Can you tell me a little about your background?'

The patient replies: 'Background, what's that?'

The core problem in the semantic variant of primary progressive aphasia is difficulty with word comprehension (semantics), as illustrated by the example above (3). The semantic variant is the best-defined variant in terms of signs and symptoms, imaging findings, and neuropathology. The meanings of rare words are lost early in the course of the disease, with more common words also eventually becoming incomprehensible to the patient. Patients additionally develop pronounced difficulties with picture and object naming. Impaired word comprehension can lead to the patient asking what individual words mean during a conversation.

However, patients with this variant usually have fluent spontaneous speech with mostly correct grammar. In a normal everyday conversation, one will often not notice any language impairment. Episodic memory is relatively intact. Patients have no difficulty describing things that have happened recently or remembering appointments, for example. However, their deteriorating word comprehension leads to poor results on tests of verbal memory.

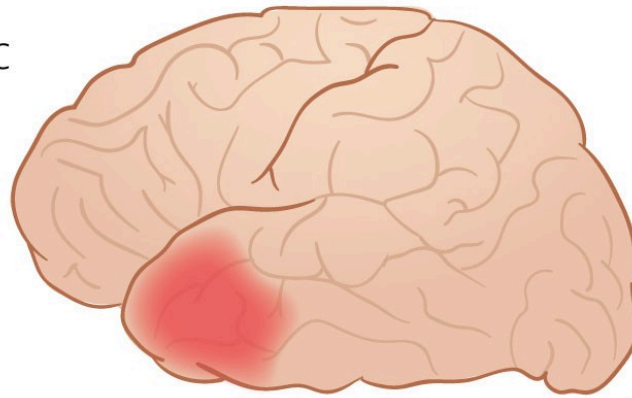
Other features of the semantic variant are impaired object knowledge, as well as surface dyslexia and dysgraphia. Impaired object knowledge refers to a lack of understanding of what objects are or are used for. Surface dyslexia means that words are read the way they are spelt. 'Bordeaux' is read as 'bor-de-a-ux',

instead of 'baw-DOH' (/bo:dów/). Surface dysgraphia means that words are spelt the way they are pronounced. 'Broad' may be written as 'brawd', for example.

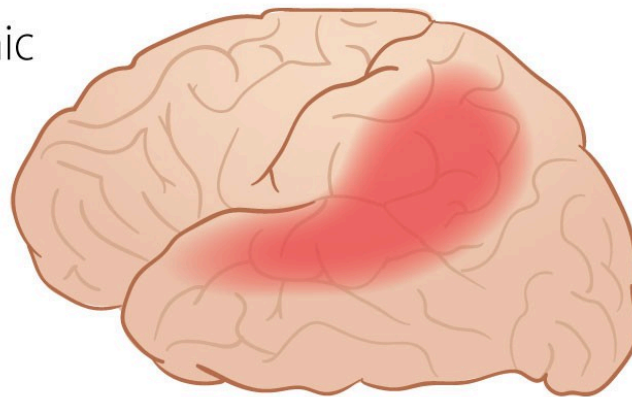
Disease progression can be slow, but eventually the language impairments become more extensive. Most patients with this type of primary progressive aphasia develop behavioural variant frontotemporal dementia. Alternatively, they may develop a semantic dementia with failure of face and object recognition, and more extensive semantic impairments [\(1, 7\)](#).

Brain magnetic resonance imaging (MRI) and positron emission tomography with ¹⁸F-fluorodeoxyglucose (FDG-PET) reveal atrophy and hypometabolism, respectively, in the anterior temporal lobes – the temporal poles – usually with a left-sided predominance (Figure 1, Table 2) [\(8\)](#). Characteristic MRI findings have good sensitivity (98 %) and specificity (93 %), and typical findings on FDG-PET are thought to have close to 100 % sensitivity and specificity [\(8\)](#). Cerebrospinal fluid analysis of dementia markers does not reveal the reduced beta-amyloid and elevated phospho-tau characteristic of Alzheimer's disease [\(9\)](#), but total tau may be slightly elevated. The biomarker neurofilament light chain (NfL) is highly elevated [\(10\)](#). In 80 % of cases pathology is found with aggregates of pathological TAR DNA-binding protein (transactive response DNA-binding protein 43 kDa, TDP-43) [\(4, 8\)](#), a form of neuropathology that is also common in frontotemporal dementia and amyotrophic lateral sclerosis.

Semantic



Logopenic



Non-fluent

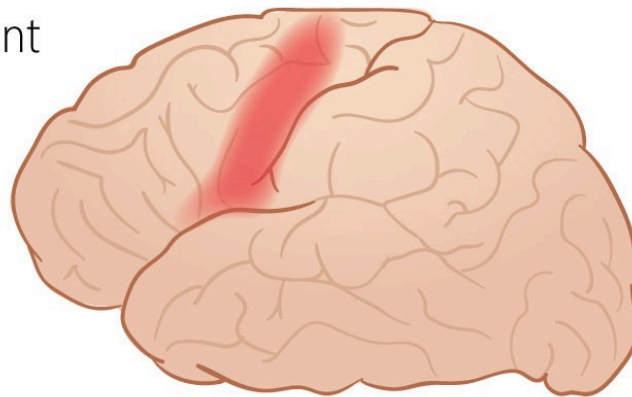


Figure 1 Simplified representation of the extent of brain hypometabolism on FDG-PET, and brain atrophy on MRI, in different variants of primary progressive aphasia. Illustration: Illumedic

Table 2

Underlying dementia subtypes and areas of neurodegeneration in variants of primary progressive aphasia (3, 8). TDP-43 = *transactive response DNA-binding protein 43 kDa*.

Aphasia variant	Most common underlying dementia	Typical site of pathology
Semantic	Frontotemporal dementia (TDP-43)	Temporal poles
Logopenic	Alzheimer's disease (amyloid and hyperphosphorylated tau). Rare: Dementia with Lewy bodies (synuclein)	Area around left posterior Sylvian fissure and/or left parietal lobe
Non-fluent/agrammatic	Most common: Frontotemporal dementia (tau) Next-most common: Alzheimer's disease (amyloid and hyperphosphorylated tau) or frontotemporal dementia (TDP-43)	Posterior parietal part of left frontal lobe

Logopenic variant

The doctor asks: 'Can you tell me a little about your background?'

The patient replies: 'Yes, you know, I worked for many years at a ..., a, what's it called again, a..., yes, you know...'

Patients with the logopenic variant of primary progressive aphasia typically have difficulty finding words, especially nouns, both in spontaneous speech and when naming (3). They also have an impaired ability to repeat words, sentences, and strings of numbers. Phonological errors are common in spontaneous speech and naming, and language sounds may be omitted or exchanged. However, patients usually have preserved understanding of single words and preserved object knowledge, as well as normal speech motor control and speech melody. Their use of language is also grammatically correct, although spontaneous speech is interrupted by phonological errors and by searching for words. Missing words are replaced by general descriptors such as 'that thing there'.

The logopenic variant is most often an aphasic variant of Alzheimer's dementia (11), and patients eventually develop typical symptoms of Alzheimer's disease.

Brain MRI has poor sensitivity (57 %) but good specificity (95 %) for this variant, while FDG-PET is reportedly more sensitive (92 %) and equally specific (94 %) (8). Typical imaging findings are left-sided posterior perisylvian or parietal atrophy and hypometabolism (Figure 1, Table 2) (3, 8).

Cerebrospinal fluid analysis of dementia markers typically reveals an Alzheimer's disease profile, i.e., reduced beta-amyloid and increased total tau and phosphorylated tau (9). Levels of the marker NfL are also elevated but not to the same extent as in the semantic and non-fluent progressive variants (10).

Non-fluent/agrammatic variant

The doctor asks: 'Can you tell me a little about your background?'

The patient replies: 'That ... I ... ing- eng- engineer ... long time.'

This is the most complex variant of primary progressive aphasia and is dominated by agrammatism and/or apraxia of speech.

Agrammatism means that the patient uses short sentences that lack function words and inflections. Subtle difficulties with grammar may be more obvious in writing than in speech. Grammatical comprehension is also impaired, particularly for long or complex sentences, negations, and passive constructions. Word comprehension and object knowledge, however, remain intact.

Apraxia of speech refers to difficulties with speech flow and pronunciation of speech sounds (12). Speech is strained and halting, with varying errors in speech sounds. Patients and relatives sometimes describe this as 'stuttering'. The patient tries several times to say the same word, with different pronunciation errors each time. Apraxia of speech also affects prosody (sentence melody) and word stress, such that speech appears monotonous ('robotic') or incorrectly stressed. The patient may have comorbid oral apraxia, meaning he or she is unable to perform actions such as smacking the lips, clicking the tongue, or coughing on command.

Patients who have apraxia of speech without agrammatism do not, strictly speaking, have aphasia, and it has been proposed that this should instead be classified as a separate diagnostic entity, 'primary progressive apraxia of speech' (4, 7).

The non-fluent/agrammatic variant of aphasia shows greater variation in terms of underlying pathology and further disease progression than the other variants. The most common underlying pathology is frontotemporal lobar degeneration with tau inclusions (52 %), followed by amyloid pathology of the Alzheimer's type (25 %) and TDP-43 pathology (19 %) (8). Some patients develop behavioural variant frontotemporal dementia, while others develop Parkinson-plus syndromes with general motor disturbances (such as corticobasal syndrome). Progression to Parkinson-plus syndromes is more common when the clinical picture is dominated by apraxia of speech (4).

Patients have atrophy and hypometabolism in the posterior frontal lobe, particularly in the dominant hemisphere (Figure 1, Table 2) (3, 8). Broca's area is usually affected. If the patient has apraxia of speech, the premotor and motor cortex may also be affected (4). Brain MRI has low sensitivity (29 %), but better specificity (91 %), whereas brain FDG-PET is reported to have 67 % sensitivity and 92 % specificity for the diagnosis (8). The pattern of dementia markers in cerebrospinal fluid varies depending on the underlying neuropathology.

Language tests

In essence, primary progressive aphasia should be diagnosed primarily by testing the functions described in Table 1.

Speech fluency. The patient's fluency is assessed by listening to how he or she speaks. A simple test of speech fluency is to ask the patient to say "pa-ta-ka" quickly multiple times in a row. It should normally be possible to say "pataka" 15 ± 5 times in ten seconds (13). Significant difficulties in doing so may indicate apraxia of speech. A more comprehensive Norwegian test for apraxia of speech has recently been published (14).

Naming. The patient is shown pictures and is asked to name what they portray. It is important to distinguish between object knowledge (describing what the picture represents) and naming (being able to give the correct name).

Repetition. Words and sentences of varying length are spoken, and the patient is asked to repeat them. The level of difficulty can be increased by using nonsense words.

Word and concept comprehension. The patient is asked what specific words mean, preferably low-frequency words such as 'offensive', 'amateur' and 'pedagogue'. Conceptual understanding can also be examined with tests of semantic access such as the 'Pyramids and Palm Trees' test (15). This involves showing the patient three pictures or words, two of which belong together semantically. For example, the patient may be shown a picture of a pyramid, with a picture of a fir tree and a palm tree underneath and asked which of the two pictures below fits in best with the one above.

Grammar. This can be tested by determining whether the patient can produce complete sentences upon describing a picture. One can also ask questions about the meaning of grammatically complex sentences: "The dog that the man ran after was old and grey. Who ran first?"

Reading and writing. Finally, the patient's ability to read a continuous text and to read and write irregularly spelt words should be tested.

Summary

Several forms of dementia can manifest with language and/or speech difficulties as the only initial symptom. These forms of dementia have different symptom profiles and are caused by different underlying neuropathologies. Knowledge of the conditions, detailed analysis of diagnostic imaging and the use of targeted cognitive tests to assess speech and language are important for making the correct diagnosis. Patients with primary progressive aphasia are often initially misdiagnosed, for example, their aphasia may be misattributed to a stroke. If the initial workup suggests a language disorder as part of a degenerative dementia, the patient should be referred to the specialist healthcare service for further testing. Speech and language assessment may be necessary to obtain the correct diagnosis, and speech and language therapy can be effective when targeted at the specific difficulties experienced by the patient (6, 16).

This article has been peer-reviewed.

REFERENCES

1. Mesulam MM, Coventry C, Bigio EH et al. Nosology of Primary Progressive Aphasia and the Neuropathology of Language. *Adv Exp Med Biol* 2021; 1281: 33–49. [PubMed][CrossRef]
2. Mouton A, Plonka A, Fabre R et al. The course of primary progressive aphasia diagnosis: a cross-sectional study. *Alzheimers Res Ther* 2022; 14: 64. [PubMed][CrossRef]
3. Gorno-Tempini ML, Hillis AE, Weintraub S et al. Classification of primary progressive aphasia and its variants. *Neurology* 2011; 76: 1006–14. [PubMed][CrossRef]
4. Botha H, Josephs KA. Primary Progressive Aphasias and Apraxia of Speech. *Continuum (Minneapolis Minn)* 2019; 25: 101–27. [PubMed][CrossRef]
5. Matias-Guiu JA, Díaz-Álvarez J, Ayala JL et al. Clustering Analysis of FDG-PET Imaging in Primary Progressive Aphasia. *Front Aging Neurosci* 2018; 10: 230. [PubMed][CrossRef]
6. Cadório I, Lousada M, Martins P et al. Generalization and maintenance of treatment gains in primary progressive aphasia (PPA): a systematic review. *Int J Lang Commun Disord* 2017; 52: 543–60. [PubMed][CrossRef]
7. Poole ML, Brodtmann A, Darby D et al. Motor Speech Phenotypes of Frontotemporal Dementia, Primary Progressive Aphasia, and Progressive Apraxia of Speech. *J Speech Lang Hear Res* 2017; 60: 897–911. [PubMed][CrossRef]
8. Wasim A, McConathy JE, Love MN et al. Neuroimaging of Primary Progressive Aphasia Variants. *Neurographics* 2018; 8: 1–6. [CrossRef]
9. Olsson B, Lautner R, Andreasson U et al. CSF and blood biomarkers for the diagnosis of Alzheimer's disease: a systematic review and meta-analysis. *Lancet Neurol* 2016; 15: 673–84. [PubMed][CrossRef]
10. Gaetani L, Blennow K, Calabresi P et al. Neurofilament light chain as a biomarker in neurological disorders. *J Neurol Neurosurg Psychiatry* 2019; 90: 870–81. [PubMed][CrossRef]
11. Mendez MF. Early-onset Alzheimer Disease and Its Variants. *Continuum (Minneapolis Minn)* 2019; 25: 34–51. [PubMed][CrossRef]
12. Duffy JR. *Motor Speech Disorders: Substrates, Differential Diagnosis, and Management*. St Louis, MO: Elsevier, 2019.
13. Östberg P, Bogdanović N, Wahlund L-O. Articulatory agility in cognitive decline. *Folia Phoniatri Logop* 2009; 61: 269–74. [PubMed][CrossRef]
14. Feiken J, Jonkers R. *Diagnostisk verktøy for taleapraksi. DIAS*. Oslo: Novus forlag, 2020.

15. Howard DM, Patterson K. Pyramide- og palmetesten. Oslo: Novus forlag, 2005.

16. Norvik M, Winsnes I, Bekkhus-Wetterberg P et al. Hva er primær progressiv afasi (PPA) – og hva har det å si for oss logopeder? Norsk tidsskrift for logopedi 2021; 2: 18–25.

Publisert: 23 November 2022. Tidsskr Nor Legeforen. DOI: 10.4045/tidsskr.22.0100

Received 5.2.2022, first revision submitted 21.8.2022, accepted 19.9.2022.

Published under open access CC BY-ND. Downloaded from tidsskriftet.no 26 June 2026.