
The treatment of appendicitis should be standardised

PERSPECTIVES

AIRAZAT M. KAZARYAN

kazaryan@gmail.com

Airazat M. Kazaryan PhD, specialist in the Gastrointestinal Surgery Section, Østfold Hospital Trust and senior consultant in the Department of Surgery, Fonna Hospital Trust, Odde.

The author has completed the ICMJE form and declares no conflicts of interest.

LARS L. EFTANG

Lars L. Eftang PhD, senior consultant in the Department of Gastrointestinal Surgery, Akershus University Hospital.

The author has completed the ICMJE form and declares no conflicts of interest.

PÅL ØDEGAARD

Pål Ødegaard, specialty registrar part 2 in the Department of Surgery, Østfold Hospital Trust.

The author has completed the ICMJE form and declares no conflicts of interest.

MARTIN HAGVE

Martin Hagve, specialty registrar part 3 in the Department of Gastrointestinal Surgery, University Hospital of North Norway and associate professor at the University of Tromsø – The Arctic University of Norway.

The author has completed the ICMJE form and declares no conflicts of interest.

BENEDICTE SKJOLD-ØDEGAARD

Benedicte Skjold-Ødegaard, senior consultant in the Gastrointestinal Surgery Section, Fonna Hospital Trust, Haugesund.

The author has completed the ICMJE form and declares no conflicts of interest.

OLE CHRISTIAN OLSEN

Ole Christian Olsen, senior consultant in the Department of Surgery, Drammen Hospital, Vestre Viken Hospital Trust.

The author has completed the ICMJE form and declares no conflicts of interest.

SVETLANA A. SHARAPOVA

Svetlana A. Sharapova, senior consultant in the Department of Surgery, Innlandet Hospital Trust, Hamar.

The author has completed the ICMJE form and declares no conflicts of interest.

RAFAEL GEORG BREUER

Rafael Georg Breuer, acting senior consultant in the Gastrointestinal Surgery Section, Hospital of Southern Norway in Kristiansand and in Arendal.

The author has completed the ICMJE form and declares no conflicts of interest.

OLOF VINGE-HOLMQUIST

Olof Vinge-Holmquist, acting senior consultant in the Department of Surgery, Orkdal Hospital, St Olav's Hospital Trust, Trondheim University Hospital.

The author has completed the ICMJE form and declares no conflicts of interest.

YASIR G. MALIK

Yasir G. Malik, senior consultant in the Department of Gastrointestinal Surgery, Akershus University Hospital.

The author has completed the ICMJE form and declares no conflicts of interest.

JOACHIM WIBORG

Joachim Wiborg, senior consultant in the Gastrointestinal Surgery Section, Telemark Hospital Trust, Skien.

The author has completed the ICMJE form and declares no conflicts of interest.

LARS BERGENE GRØNVOLD

Lars Bergene Grønvold, senior consultant in the Gastrointestinal Surgery Section, Vestfold Hospital Trust, Tønsberg.

The author has completed the ICMJE form and declares no conflicts of interest.

PETER WIEL MONRAD-HANSEN

Peter Wiel Monrad-Hansen PhD, senior consultant in the Department of Gastrointestinal Surgery, Oslo University Hospital, Ullevål.

The author has completed the ICMJE form and declares no conflicts of interest.

SØREN NOBÆK

Søren Nobæk, lead senior consultant in the Department of Surgery, Finnmark Hospital Trust, Kirkenes.

The author has completed the ICMJE form and declares no conflicts of interest.

KHAYAM BUTT

Khayam Butt, senior consultant in the Gastrointestinal Surgery Section, Nordland Hospital Trust, Bodø.

The author has completed the ICMJE form and declares no conflicts of interest.

HANS H. WASMUTH

Hans H. Wasmuth PhD, specialist in general surgery and gastroenterological surgery, previously senior consultant in the Department of Gastrointestinal Surgery, St Olav's Hospital, Trondheim University Hospital.

The author has completed the ICMJE form and declares no conflicts of interest.

BJØRN STEINAR NEDREBØ

Bjørn Steinar Nedrebø PhD, senior consultant in the Department of Gastrointestinal Surgery, Haukeland University Hospital.

The author has completed the ICMJE form and declares no conflicts of interest.

ERIK TRONDSSEN

Erik Trondsen PhD, senior consultant in the Department of Surgery, Fonna Hospital Trust, Stord.

The author has completed the ICMJE form and declares no conflicts of interest.

PETER RANCINGER

Peter Rancinger, lead senior consultant in the Gastrointestinal Surgery Section, Østfold Hospital Trust.

The author has completed the ICMJE form and declares no conflicts of interest.

TOM MALA

Tom Mala PhD, senior consultant in the Department of Gastrointestinal Surgery, Oslo University Hospital, Ullevål and professor at the University of Oslo.

The author has completed the ICMJE form and declares no conflicts of interest.

KJETIL SØREIDE

Kjetil Søreide PhD, senior consultant in the Department of Gastrointestinal Surgery, Stavanger University Hospital and professor at the University of Bergen.

The author has completed the ICMJE form and declares no conflicts of interest.

Routine practices for the diagnostic investigation and treatment of acute appendicitis seem to vary between hospitals. We propose working towards a joint strategy for the diagnostic investigation and treatment of acute appendicitis in Norway, on the basis of updated international recommendations and experiences from Norwegian hospitals.

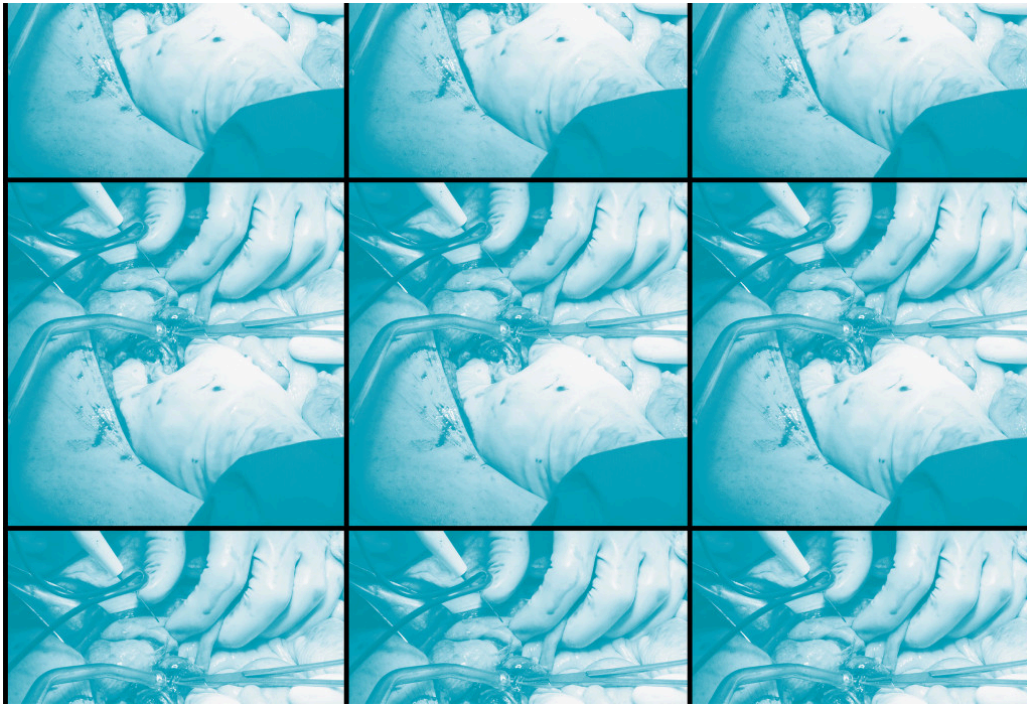


Illustration: Science Photo Library / NTB. Adapted by the Journal of the Norwegian Medical Association.

In Norway, there are no national guidelines for the management of acute appendicitis, and routine practice varies between hospitals. In this 'Perspectives' article, we propose a strategy for diagnostic investigation and treatment, adapted to the situation in Norway. The strategy is based on international recommendations and on experiences from a wide range of large and small hospitals in Norway. The article is intended to be a contribution to the wider discussion about consensus-based national recommendations.

«The article is intended to be a contribution to the wider discussion about consensus-based national recommendations»

Acute appendicitis is common around the world, but approaches to diagnostic investigation and treatment vary between institutions and regions [\(1–3\)](#). The European Association for Endoscopic Surgery (EAES) and the Society of American Gastrointestinal and Endoscopic Surgeons (SAGES) have produced recommendations about the management of acute appendicitis [\(4, 5\)](#). The World Society of Emergency Surgery (WSES) has tried to develop standardised guidelines for the diagnostic investigation and treatment of acute appendicitis in a consensus report [\(6\)](#). These are complex with a weak evidence base, but they seem to be based on the best available knowledge. However, there is extensive debate about certain principles in the surgical community, with significant differences in practice between countries. For example, the use of diagnostic imaging continues to be controversial and widely debated [\(7\)](#).

Diagnostic investigation of acute appendicitis

The clinical diagnostic investigation of suspected acute appendicitis is difficult. The condition has differing symptoms and varying clinical findings, and there are a number of differential diagnoses to take into consideration. Scoring tools are used for diagnosis, but none of these are widely used in daily practice (8). Several of the scoring tools have high sensitivity but low specificity. Use of scoring tools may help identify patients at low risk of appendicitis who are best managed with continued observation (9).

«In international studies, the percentage of patients referred for CT for suspected appendicitis varies from 10 % to 95 %»

Diagnostic imaging with the use of both ultrasound and computed tomography (CT) has become increasingly important to varying degrees. In international studies, the percentage of patients referred for CT for suspected appendicitis varies from 10 % to 95 %. There is a similar variation in the use of abdominal ultrasound (9). The diagnostic value of ultrasound depends on factors specific to both the patient and the radiologist, and there are considerable variations in the sensitivity and specificity for acute appendicitis. There is a high rate of inconclusive examinations, and a normal appendix is reported in around half of examinations even when the patient does have appendicitis (10). Nevertheless, the World Society of Emergency Surgery recommends routine ultrasound ahead of CT if the radiologist has sufficient experience in this type of diagnostic investigation of the condition (6).

Benefits and drawbacks

The absence of radiation exposure is a benefit of ultrasound. However, there is variable availability and experience with this diagnostic investigation of appendicitis in the out-of-hours duty shifts in Norwegian hospitals. Therefore, when drawing up guidelines that include routine ultrasound ahead of potential CT, account should be taken of available local resources to avoid delays in treatment. Many institutions, particularly in Japan and the United States, perform CT routinely in cases of suspected appendicitis (1, 11). This reduces the percentage of negative appendectomies from 10–19 % to 2.5–5 % (1, 11).

Diagnostic CT scans might also elucidate a number of other differential diagnoses. However, although CT has been shown to have high specificity and sensitivity, it will also produce a certain number of false negative and false positive cases (12). Furthermore, routine preoperative CT scanning may increase the risk of cancer development due to radiation exposure, even with the use of low-dose CT. However, the significance of this increased risk with modern CT scans is uncertain (13).

In Norway, a largely selective approach is practised towards preoperative diagnostic imaging in suspected appendicitis. CT scanning is often preferable in older patients. The incidence of malignancy in the large intestine and appendix increases with age, particularly after the age of 40–50 years, and malignancy in the appendix or caecum can present as appendicitis (14). The frequency of complicated appendicitis (i.e. gangrenous appendicitis, perforation or abscess formation) is also higher in older patients (1, 6). Therefore, diagnostic CT scans in this age group might help reveal other conditions and complicating factors, which will guide the treatment strategy.

Ultrasound may be a good alternative to CT in children and slim adolescents, particularly to distinguish appendicitis from a differential diagnosis of mesenteric lymphadenitis, which is a common diagnosis in this younger patient group (15). This group, along with pregnant women, is also more vulnerable to radiation, which clinicians must take into account when selecting a diagnostic approach (16). Box 1 shows the proposed pragmatic approach to the diagnostic investigation of suspected acute appendicitis.

Box 1 Proposed diagnostic investigation of suspected acute appendicitis

- Patients with typical clinical findings and aged <40 years should be taken for immediate appendectomy, preferably laparoscopic.
 - Pregnancy should be ruled out in women of child-bearing age (e.g. ectopic pregnancy), and ultrasound and/or gynaecological examination should be considered before any laparoscopy.
 - In cases of atypical symptoms, uncertain diagnosis or suspected complicated appendicitis (infiltrate with or without abscess), and cases with a history of symptoms for more than three days, consideration should be given to preoperative CT (adults) or ultrasound (children and slim adolescents). Ultrasound can also be considered in adults who are of normal weight or underweight aged <40 years if sufficient experience and expertise with diagnostic ultrasound scanning for appendicitis is available.
 - In pregnant women with suspected acute appendicitis, the threshold for gynaecological examination and ultrasound prior to surgery should be low, unless the case history and clinical findings are unambiguous (delayed treatment may lead to appendiceal perforation, with an associated risk of miscarriage). MRI or low-dose CT may be appropriate in some cases.
 - For patients aged ≥ 40 years, CT should be considered prior to surgery due to a higher incidence of neoplasms and complicated appendicitis.
-

Uncomplicated appendicitis

Surgery has been the standard treatment for acute appendicitis for over 100 years. There are obvious advantages to treatment with a laparoscopic technique (4–6). In general, laparoscopic appendectomy is technically straightforward to perform and should be the first-line treatment. Open appendectomy is still used routinely at some institutions internationally, although there is a clear tendency towards limiting its use to specific cases (1, 2, 8).

«It is not clear-cut whether patients should be offered antibiotic monotherapy treatment as an alternative»

Antibiotic monotherapy treatment has emerged as an alternative in the last decade. Systematic reviews and meta-analyses of randomised studies have concluded that the majority of patients with uncomplicated acute appendicitis can be treated with an antibiotic-first approach (17), but the studies also show that the rate of recurrence is approximately 40 % after five years (18). Therefore, it is not clear-cut whether patients should be offered antibiotic monotherapy treatment as an alternative (19). It is uncertain to what extent antibiotic monotherapy treatment is used in practice at Norwegian hospitals currently.

Non-surgical treatment of complicated appendicitis

Colonoscopy to the caecum or CT colonography after 6–8 weeks is recommended for patients aged ≥ 40 years treated for appendicitis without surgery to rule out malignancy (6, 20). Conservative treatment with antibiotics, sometimes in combination with drainage, is recommended by many as a low-risk alternative in cases with illness lasting more than three days, due to possible infiltrate formation with or without abscess (21). However, randomised data show that laparoscopic treatment in these cases leads to shorter recovery times where there is the surgical expertise to manage more complicated conditions (22).

The World Society of Emergency Surgery, the European Association for Endoscopic Surgery and the Society of American Gastrointestinal and Endoscopic Surgeons all recommend appendectomy if there are persistent symptoms or a clinical suspicion of appendicitis, even if no appendiceal inflammation is visually evident during surgery, in the absence of any other perioperative findings to explain the symptoms (4–6, 23). Macroscopic assessment of the appendix may be uncertain, and a normal-looking appendix left in situ may carry a risk of repeat surgery, subsequent acute appendicitis or missed malignancy (24).

Conclusion

Acute appendicitis is still a clinical challenge for doctors, both in the primary care sector and in hospitals. Management of the condition varies, and little is known about practice in Norway. For this common acute surgical condition, joint guidelines for diagnostic investigation and treatment may lead to better use of resources and patient experience across hospitals. We should work on this together.

The authors would like to express thanks for the contribution made to this article by Eivind Warberg. He died in a drowning accident in July 2021.

REFERENCES

1. Sugiura K, Miyake H, Nagai H et al. Chronological changes in appendiceal pathology among patients who underwent appendectomy for suspected acute appendicitis. *World J Surg* 2020; 44: 2965–73. [PubMed][CrossRef]
2. Sartelli M, Baiocchi GL, Di Saverio S et al. Prospective Observational Study on acute Appendicitis Worldwide (POSAW). *World J Emerg Surg* 2018; 13: 19. [PubMed][CrossRef]
3. Bhangu A, Søreide K, Di Saverio S et al. Acute appendicitis: modern understanding of pathogenesis, diagnosis, and management. *Lancet* 2015; 386: 1278–87. [PubMed][CrossRef]
4. Gorter RR, Eker HH, Gorter-Stam MA et al. Diagnosis and management of acute appendicitis. EAES consensus development conference 2015. *Surg Endosc* 2016; 30: 4668–90. [PubMed][CrossRef]
5. Korndorffer JR, Fellingner E, Reed W. SAGES guideline for laparoscopic appendectomy. *Surg Endosc* 2010; 24: 757–61. [PubMed][CrossRef]
6. Di Saverio S, Podda M, De Simone B et al. Diagnosis and treatment of acute appendicitis: 2020 update of the WSES Jerusalem guidelines. *World J Emerg Surg* 2020; 15: 27. [PubMed][CrossRef]
7. Kazaryan AM, Warberg EA, Mala T. Surgery for Appendicitis: Where Do We Go? Rational Imaging and Surgical Approach. *World J Surg* 2020; 44: 2974–5. [PubMed][CrossRef]
8. Kollár D, McCartan DP, Bourke M et al. Predicting acute appendicitis? A comparison of the Alvarado score, the Appendicitis Inflammatory Response Score and clinical assessment. *World J Surg* 2015; 39: 104–9. [PubMed][CrossRef]
9. Podda M, Andersson R, Boermeester M et al. Do young patients with high clinical suspicion of appendicitis really need cross-sectional imaging? Proceedings from a highly controversial debate among the experts' panel of

- 2020 WSES Jerusalem guidelines. *J Trauma Acute Care Surg* 2021; 90: e101–7. [PubMed][CrossRef]
10. Giljaca V, Nadarevic T, Poropat G et al. Diagnostic accuracy of abdominal ultrasound for diagnosis of acute Appendicitis: systematic review and Meta-analysis. *World J Surg* 2017; 41: 693–700. [PubMed][CrossRef]
11. Sharma P, Hegde R, Kulkarni A et al. Imaging right lower quadrant pain: Not always appendicitis. *Clin Imaging* 2020; 63: 65–82. [PubMed][CrossRef]
12. Pickhardt PJ, Lawrence EM, Pooler BD et al. Diagnostic performance of multidetector computed tomography for suspected acute appendicitis. *Ann Intern Med* 2011; 154: 789–96, W-291. [PubMed][CrossRef]
13. Rogers W, Hoffman J, Noori N. Harms of CT scanning prior to surgery for suspected appendicitis. *Evid Based Med* 2015; 20: 3–4. [PubMed][CrossRef]
14. Watchorn RE, Poder L, Wang ZJ et al. Computed tomography findings mimicking appendicitis as a manifestation of colorectal cancer. *Clin Imaging* 2009; 33: 430–2. [PubMed][CrossRef]
15. Lawton B, Goldstein H, Davis T et al. Diagnosis of appendicitis in the paediatric emergency department: an update. *Curr Opin Pediatr* 2019; 31: 312–6. [PubMed][CrossRef]
16. Poletti PA, Botsikas D, Becker M et al. Suspicion of appendicitis in pregnant women: emergency evaluation by sonography and low-dose CT with oral contrast. *Eur Radiol* 2019; 29: 345–52. [PubMed][CrossRef]
17. Podda M, Gerardi C, Cillara N et al. Antibiotic treatment and appendectomy for uncomplicated acute appendicitis in adults and children: a systematic review and meta-analysis. *Ann Surg* 2019; 270: 1028–40. [PubMed][CrossRef]
18. Salminen P, Paajanen H, Rautio T et al. Antibiotic therapy vs appendectomy for treatment of uncomplicated acute appendicitis: the APPAC randomized clinical trial. *JAMA* 2015; 313: 2340–8. [PubMed][CrossRef]
19. Kessler U, Mosbahi S, Walker B et al. Conservative treatment versus surgery for uncomplicated appendicitis in children: a systematic review and meta-analysis. *Arch Dis Child* 2017; 102: 1118–24. [PubMed][CrossRef]
20. Mällinen J, Rautio T, Grönroos J et al. Risk of Appendiceal Neoplasm in Periappendicular Abscess in Patients Treated With Interval Appendectomy vs Follow-up With Magnetic Resonance Imaging: 1-Year Outcomes of the Peri-Appendicitis Acuta Randomized Clinical Trial. *JAMA Surg* 2019; 154: 200–7. [PubMed][CrossRef]
21. Simillis C, Symeonides P, Shorthouse AJ et al. A meta-analysis comparing conservative treatment versus acute appendectomy for complicated appendicitis (abscess or phlegmon). *Surgery* 2010; 147: 818–29. [PubMed][CrossRef]

22. Mentula P, Sammalkorpi H, Leppäniemi A. Laparoscopic Surgery or Conservative Treatment for Appendiceal Abscess in Adults? A Randomized Controlled Trial. *Ann Surg* 2015; 262: 237–42. [PubMed][CrossRef]
 23. Jaunoo SS, Hale AL, Masters JP et al. An international survey of opinion regarding investigation of possible appendicitis and laparoscopic management of a macroscopically normal appendix. *Ann R Coll Surg Engl* 2012; 94: 476–80. [PubMed][CrossRef]
 24. Strong S, Blencowe N, Bhangu A. How good are surgeons at identifying appendicitis? Results from a multi-centre cohort study. *Int J Surg* 2015; 15: 107–12. [PubMed][CrossRef]
-

Publisert: 1 August 2022. Tidsskr Nor Legeforen. DOI: 10.4045/tidsskr.22.0232

Received 17.3.2022, first revision submitted 11.4.2022, accepted 4.5.2022.

Copyright: © Tidsskriftet 2026 Downloaded from tidsskriftet.no 24 June 2026.