

## When sitting down hurts

---

### IMAGES IN MEDICINE

HENRIK MOLTU CHRISTENSEN

hemchr@ous-hf.no

Department of Pathology

Oslo University Hospital, Radiumhospitalet

Henrik Moltu Christensen, specialty registrar.

The author has completed the ICMJE form and declares no conflicts of interest.

MARIUS LUND-IVERSEN

Department of Pathology

Oslo University Hospital, Radiumhospitalet

Marius Lund-Iversen, senior consultant and specialist in pathology.

The author has completed the ICMJE form and declares no conflicts of interest.

ISABEL LLORET

Department of Radiation Oncology

Oslo University Hospital, Radiumhospitalet

Isabel Lloret, senior consultant and specialist in radiology.

The author has completed the ICMJE form and declares no conflicts of interest.

STEPHAN STOLDT

Department of Gastrointestinal and Children Surgery

Division of Surgery, Inflammatory Diseases and Transplantation

Oslo University Hospital, Radiumhospitalet

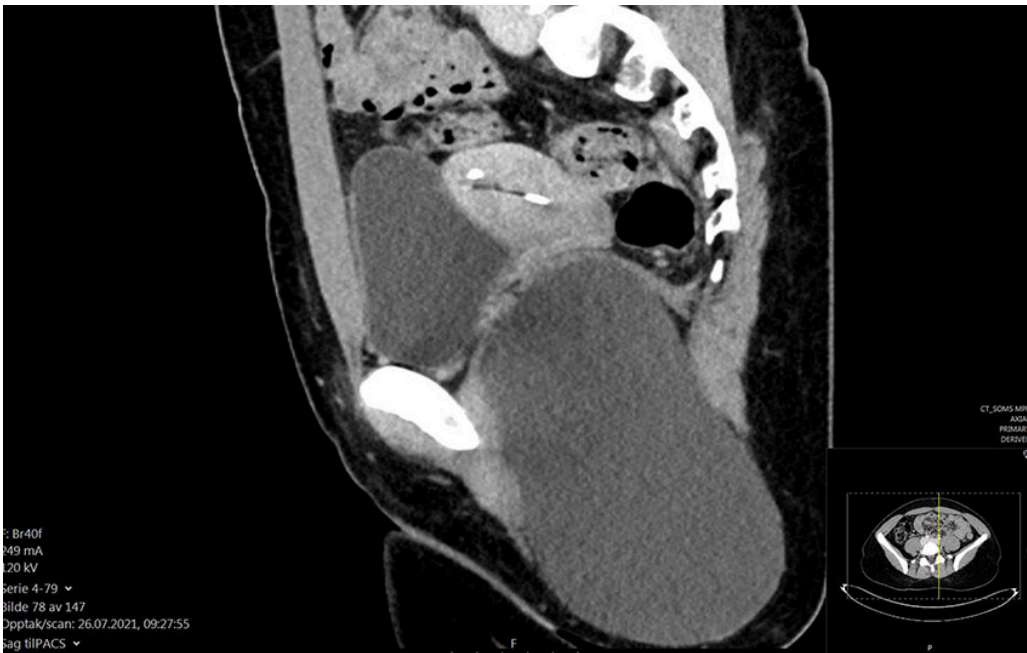
Stephan Stoldt, senior consultant and specialist in general surgery and gastroenterological surgery.

The author has completed the ICMJE form and declares no conflicts of interest.

---

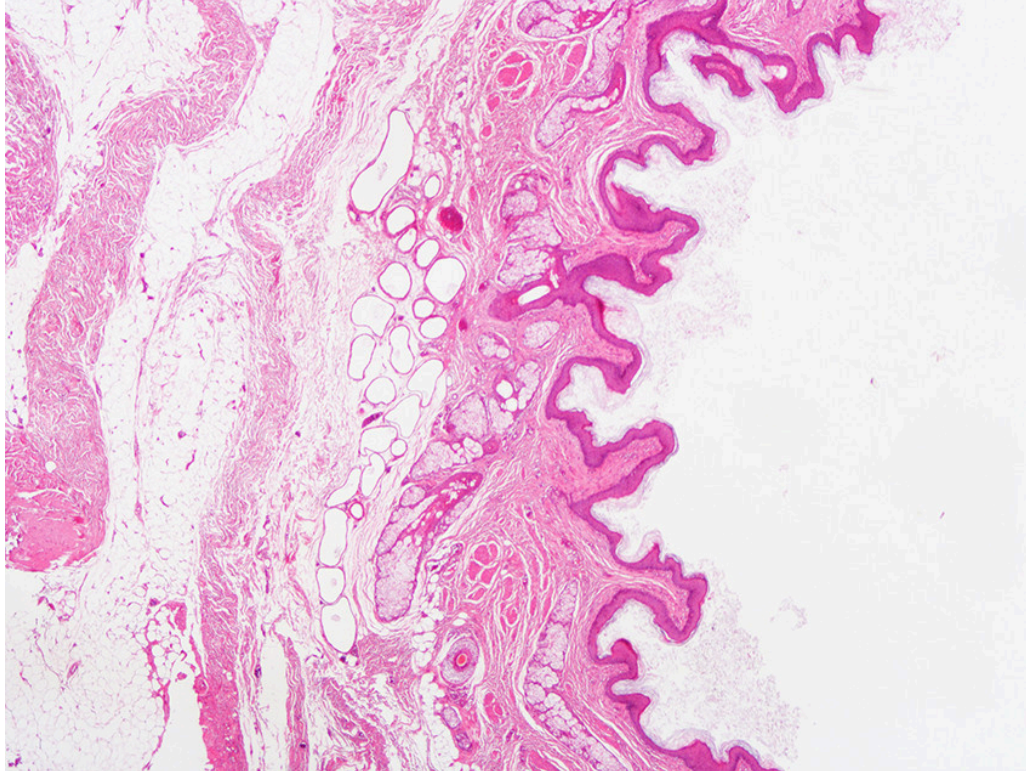


The image shows a unilocular cyst with a smooth and even inner wall, containing an abundance of spherical sebaceous and hair-like structures (Image 1). It was removed in toto and entirely without rupture. A preoperative sagittal CT scan of the pelvis showed a large, unilocular cystic mass in the left ischioanal fossa, giving rise to minor cranial displacement of the levator ani muscle (Image 2). The lesion was  $16.3 \times 9.8 \times 8.8$  cm in size. Postoperative histological examination revealed a cyst covered in squamous epithelium with underlying hair follicles with arrector pili muscles as well as sebaceous and eccrine glands (Image 3).



The histological findings, together with the anatomical location and radiology, were consistent with a dermoid cyst in the ischioanal fossa. Dermoid cysts are benign malformations that arise from the entrapment of ectodermal elements

along the lines of embryonic closure in the fetus; their incidence in children is approximately 3 per 100,000 (1, 2). Seventy per cent of cases are discovered before the age of five years, but others are not detected until adulthood (1). Histologically, the cysts are composed of an epidermal and dermis-like wall with eccrine glands plus hair shafts and follicles (1, 2). The cysts are most commonly seen on the head or on the back of the neck, but can occur anywhere on the body and are usually slow-growing (3). Surgical resection of the cyst is indicated (1).



The patient was a woman in her twenties who had suffered discomfort and pain in her left buttock for a number of years and had eventually discovered a palpable mass. The patient had sought medical advice several times, but on each occasion her symptoms had been interpreted as muscular. The symptoms worsened until eventually she was unable to sit on her left side. The cyst was detected, and surgical treatment recommended. In the months prior to surgery, the patient noticed that the lesion had grown and that the overlying skin would often become blue and discoloured.

Since resection of the cyst via a perianal incision in the perineum, the patient has had reduced sensitivity in the surgical area and in the left side of the lower pelvis.

---

*The patient has consented to the publication of this article.*

*The article has been peer-reviewed.*

---

## REFERENCES

1. Shareef S, Etefagh L. Dermoid cyst. Treasure Island, FL: StatPearlsPublishing, 2021.

2. Reissis D, Pfaff MJ, Patel A et al. Craniofacial dermoid cysts: histological analysis and inter-site comparison. *Yale J Biol Med* 2014; 87: 349–57.

[PubMed]

3. Dermoid cyst. Pathology outlines. Oppdatert 6.12.2021.

<https://www.pathologyoutlines.com/topic/skintumornonmelanocyticdermoidcyst.html> Accessed 28.2.2022.

---

Publisert: 4 April 2022. Tidsskr Nor Legeforen. DOI: 10.4045/tidsskr.21.0794

Received 10.11.2021, first revision submitted 10.2.2022, accepted 28.2.2022.

Copyright: © Tidsskriftet 2026 Downloaded from tidsskriftet.no 2 July 2026.