
Uterine rupture in a nulliparous woman

SHORT CASE REPORT

SOLVEIG KARBØ ONSTAD

solveigonstad@hotmail.com

Division of Obstetrics and Gynecology

Akershus University Hospital

Solveig Karbø Onstad, specialty registrar.

The author has completed the ICMJE form and declares no conflicts of interest.

ANDREA SOLNES MILTENBURG

Division of Obstetrics and Gynecology

Akershus University Hospital

Andrea Solnes Miltenburg, PhD, specialty registrar.

The author has completed the ICMJE form and declares no conflicts of interest.

ELLEN MARIE STRØM-ROUM

Division of Obstetrics and Gynecology

Akershus University Hospital

Ellen Marie Strøm-Roum, PhD, senior consultant and specialist in obstetrics and gynaecology.

The author has completed the ICMJE form and declares no conflicts of interest.

BACKGROUND

Previous caesarean section is considered the main risk factor for uterine rupture. However, other surgical procedures performed on the uterus can also lead to rupture in future pregnancies.

CASE PRESENTATION

The patient was a nulliparous woman, induced at gestational age of 41 + 6 with misoprostol. She developed severe persistent abdominal pain. Due to fetal bradycardia, an acute caesarean section was performed. Peroperatively a large rupture was identified in the uterine fundus and the placenta was detached into the abdomen. Medical history included a previous rightsided salpingectomy due to an extrauterine pregnancy located in the interstitial part of the right Fallopian tube.

INTERPRETATION

Interstitial extrauterine pregnancy is rare, and recommendations for mode of delivery for subsequent pregnancies remain unclear. The current case illustrates the importance of being aware of the risk of rupture when the patient has undergone previous gynaecological surgery other than caesarean section, and of ensuring awareness of the placenta's location.

Uterine rupture is a rare but serious obstetric complication. A previous caesarean section is the biggest risk factor, but even minor uterine surgery can increase the risk of rupture.

A previously healthy nulliparous woman in her twenties had a history of right-sided salpingectomy following an ectopic pregnancy four years earlier. Three years after the procedure, she underwent a diagnostic laparoscopy with tubal perfusion due to infertility, but subsequently conceived spontaneously. The findings of a routine examination in gestational week 42 (41 + 3) were normal, with the fetus in vertex presentation and the placenta located at the top of the uterus.

Labour was induced three days later with the indication of post-term pregnancy. An ultrasound examination on admission showed a normal volume of amniotic fluid, spontaneous fetal movements and normal Doppler signals. No placental abnormalities were noted. The woman was given 25 µg misoprostol tablets per os, after an attempt to insert a balloon catheter into the cervix had failed. She received four tablets in total at two-hourly intervals. Prior to the last tablet, vaginal examination revealed a closed cervix, while cardiotocography (CTG) showed abnormal fetal sounds and tachycardia of 155 beats per minute (reference range 110–150) with normal variability (Figure 1). The woman began to experience increasing contractions and was soon in severe pain. She was transferred to the delivery room one hour and ten minutes after the last misoprostol tablet was administered. The CTG device was disconnected in association with the transfer.

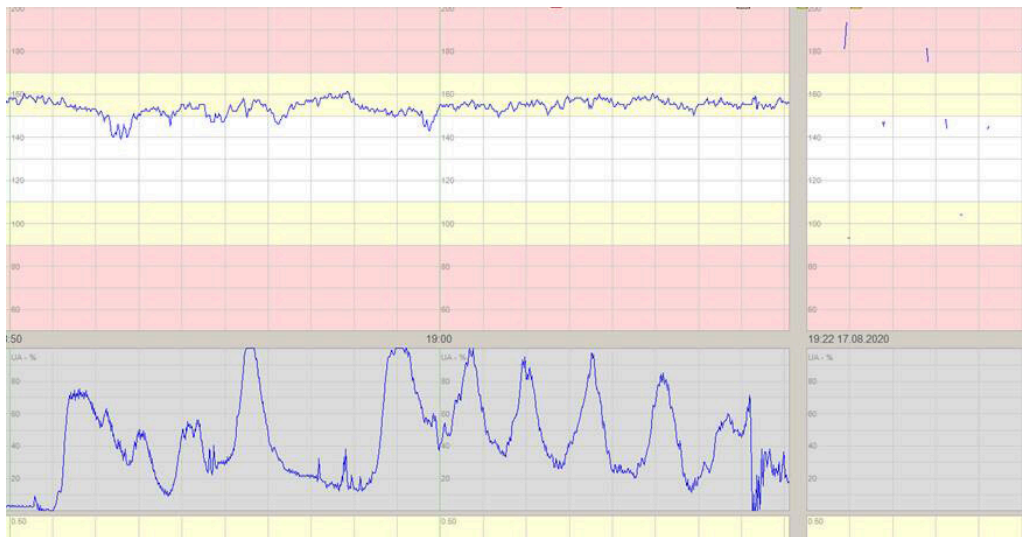


Figure 1 Cardiotocography (CTG) shows the fetal heart rate (upper trace), which is above the reference range (white field). The contraction recording (lower trace) shows frequent contractions prior to the CTG device being disconnected. Upon reconnection 13 minutes later, the midwife detected a fetal heart rate of between 70 and 90 beats per minute, and no contractions can be seen in the recording.

During the transfer, the woman's abdomen became hard and tensed and she experienced increasing pain that did not ease between contractions. When the CTG device was reconnected after 13 minutes, the midwife detected a fetal heart rate of 70–90 beats per minute, and a doctor was summoned. Ultrasound examination confirmed fetal bradycardia. The pain was interpreted as uterine hyperstimulation, accompanied by signs of fetal hypoxia, and intravenous tocolysis was administered in the form of 6.75 mg atosiban. There was no improvement in fetal heart rate after the tocolysis, and the woman was perceived to be in abnormally severe pain. Vaginal examination revealed that the cervix was still closed. Owing to persistent fetal bradycardia, the woman was immediately transferred to the operating theatre for an emergency caesarean section under general anaesthesia.

During laparotomy, clots and bloody fluid emptied from the abdominal cavity. Uterotomy was performed as usual. The amniotic fluid was clear. A pale, hypotonic infant was delivered from the vertex position. The placenta was delivered after being found detached in the abdomen. Palpation revealed intestines in the uterine cavity, as well as a 12 cm long uterine rupture extending from the right to left tubal corner along the top of the uterus (Figure 2).

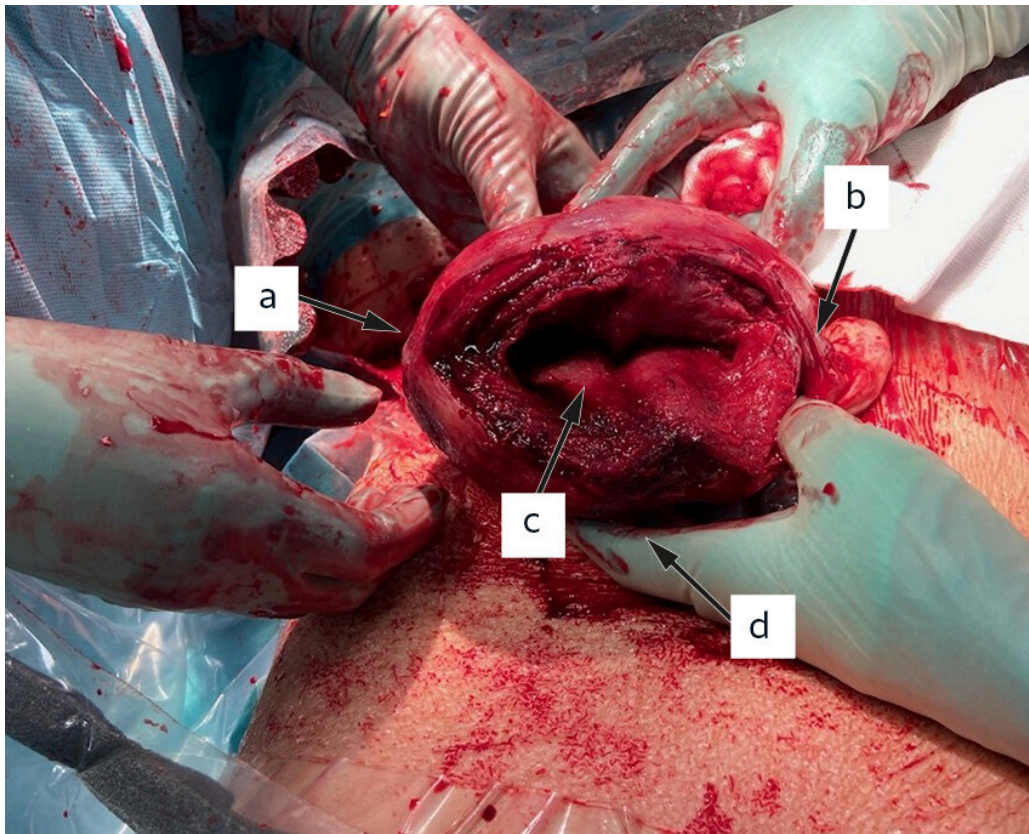


Figure 2 Large uterine rupture extending from right (a) to left (b) tubal corner into the uterine cavity (c). The uterotomy is not visible in the photograph, but is located on the anterior wall (d).

The uterotomy and uterine rupture were sutured in two layers. The total blood loss was 600 mL, and the woman remained stable throughout the procedure. The infant weighed 3 990 g, and had an Apgar score of 1 - 1-4 after 1, 5 and 10 minutes, respectively. Umbilical cord blood gas analysis revealed a pH of 6.74 (reference range 7.17–7.48) and base excess of –13.4 (–9 to –1), indicating severe fetal asphyxia. The infant was intubated and underwent therapeutic hypothermia for 72 hours in accordance with guidelines (1).

The woman had an uncomplicated postoperative course. The infant was discharged in good health ten days after delivery and showed normal development.

Discussion

Uterine rupture is a serious obstetric complication associated with high perinatal and maternal morbidity and mortality (2). In a Norwegian study, complete rupture was associated with 15 % perinatal mortality, while 23 % of infants required transfer to a neonatal intensive care unit, and 6.1 % developed hypoxic ischaemic encephalopathy (3). In the Nordic countries, the incidence of complete rupture is 5.6 per 10 000 births. Among women with a history of caesarean section, the incidence increases to 5 per 1 000 births (4). The main risk factors for uterine rupture are previous uterine surgery, and induction of labour. The combined use of prostaglandins and oxytocin for induction is in particular associated with increased risk (5, 6).

Our patient had previously undergone salpingectomy, and labour was induced with misoprostol – a prostaglandin – post-term. She had the most common symptoms of uterine rupture, which include pain that does not ease between contractions, and pathological cardiotocography. However, uterine rupture was not initially suspected as it is very rare in nulliparous women. Other symptoms may include sudden cessation of contractions, vaginal bleeding, disappearance of the presenting part of the fetus during vaginal examination, peritoneal irritation, a fall in blood pressure, shock or death [\(7\)](#). If uterine rupture is suspected, immediate delivery of both child and placenta are required, most often via a laparotomy.

The surgical notes from the salpingectomy were obtained postpartum. These described a highly proximal, bluish dilation of the fallopian tube, consistent with an interstitial ectopic pregnancy. Interstitial ectopic pregnancies are localised in the proximal part of the fallopian tube, in the muscular region of the uterine wall. Such pregnancies account for 2–4 % of all tubal pregnancies [\(8\)](#), and are most often managed surgically with cornual resection [\(9\)](#). In our patient, intramyometrial vasopressin was administered in the vicinity of the tubal corner to achieve haemostasis, and the wound was sutured at the tubal corner. The right fallopian tube was then removed, but cornual wedge excision was not performed.

Laparoscopy is preferred for surgical procedures on the uterus or adnexa, and uterine rupture is a known, albeit very rare, potential complication, especially after laparoscopic myomectomy [\(10\)](#). Few studies have described the risk of uterine rupture after laparoscopic salpingectomy. Nevertheless, several case reports and retrospective studies have described a risk of rupture in subsequent pregnancies following primary surgical management of an interstitial pregnancy, especially following cornual wedge excision [\(5, 11\)](#). A Norwegian study from 2019 included 33 patients with a history of cornual wedge excision for interstitial pregnancy [\(12\)](#). The control group consisted of patients who had undergone laparoscopic salpingectomy for non-interstitial ectopic pregnancies. The study examined the mode of delivery and the risk of uterine rupture, and found two cases of uterine rupture among the 33 women. For subsequent births, 60 % of the women with a history of cornual wedge excision were delivered by caesarean section, compared with 18 % in the control group [\(12\)](#). Given the sparsity of research in this field, consequences for later pregnancies remain unclear, and thus it is difficult to make recommendations.

In our patient, the combination of a previous surgical intervention and the induction of labour is likely to have contributed to the uterine rupture. On the basis of current knowledge, an ectopic pregnancy in the uterine horn should not necessarily lead to a recommendation for a planned caesarean section, but one should be aware of uterine rupture as a potential complication, especially if labour is induced. This case report also illustrates the importance of obtaining medical records from previous hospital admissions in order to obtain a complete medical history. In the current case, this might have led to a decision not to induce labour, and timely diagnosis and delivery.

The woman has been informed of the possible reasons for her uterine rupture and has been advised to undergo a caesarean section for any subsequent pregnancies.

The patient and the father of the child have consented to the publication of this article. The article has been peer-reviewed.

LITERATURE

1. Klingenberg C, Støen R, Moster D et al. Terapeutisk hypotermi ved perinatal asfyksi. *Pediatriveiledere fra Norsk barnelegeforening*. <https://www.legeforeningen.no/contentassets/06a7a1f5110c418db68b71d32753c81e/terapeutisk-hypotermi-ved-perinatalasfyksi-nasjonalprosedyre-finalo81117.docx> Accessed 10.1.2021.
2. Colmorn LB, Petersen KB, Jakobsson M et al. The Nordic Obstetric Surveillance Study: a study of complete uterine rupture, abnormally invasive placenta, peripartum hysterectomy, and severe blood loss at delivery. *Acta Obstet Gynecol Scand* 2015; 94: 734–44. [PubMed][CrossRef]
3. Al-Zirqi I, Daltveit AK, Vangen S. Infant outcome after complete uterine rupture. *Am J Obstet Gynecol* 2018; 219: 109.e1–8. [PubMed][CrossRef]
4. Al-Zirqi I, Stray-Pedersen B, Forsén L et al. Uterine rupture after previous caesarean section. *BJOG* 2010; 117: 809–20. [PubMed][CrossRef]
5. Chao AS, Chang YL, Yang LY et al. Laparoscopic uterine surgery as a risk factor for uterine rupture during pregnancy. *PLoS One* 2018; 13: e0197307. [PubMed][CrossRef]
6. Al-Zirqi I, Daltveit AK, Forsén L et al. Risk factors for complete uterine rupture. *Am J Obstet Gynecol* 2017; 216: 165.e1–8. [PubMed][CrossRef]
7. Al-Zirqi I, Tappert C. Uterusruptur. *Veileder i fødselshjelp*. <https://www.legeforeningen.no/foreningsledd/fagmed/norskgynekologiskforening/veiledere/veileder-i-fodselsjelp/uterusruptur> Accessed 10.1.2021.
8. Lau S, Tulandi T. Conservative medical and surgical management of interstitial ectopic pregnancy. *Fertil Steril* 1999; 72: 207–15. [PubMed][CrossRef]
9. Svenningsen R, Langebrekke A, Qvigstad E. Interstitielle graviditeter—diagnostikk og behandling. *Tidsskr Nor Laegeforen* 2007; 127: 2242–4. [PubMed]
10. Gambacorti-Passerini Z, Gimovsky AC, Locatelli A et al. Trial of labor after myomectomy and uterine rupture: a systematic review. *Acta Obstet Gynecol Scand* 2016; 95: 724–34, 4. [PubMed][CrossRef]
11. Hoyos LR, Vilchez G, Allsworth JE et al. Outcomes in subsequent pregnancies after wedge resection for interstitial ectopic pregnancy: a

retrospective cohort study. *J Matern Fetal Neonatal Med* 2019; 32: 2354–60. [PubMed][CrossRef]

12. Svenningsen R, Staff AC, Langebrekke A et al. Fertility outcome after cornual resection of interstitial pregnancies. *J Minim Invasive Gynecol* 2019; 26: 865–70. [PubMed][CrossRef]

Publisert: 28 September 2021. Tidsskr Nor Legeforen. DOI: 10.4045/tidsskr.21.0085

Received 29.1.2021, first revision submitted 11.4.2021, accepted 10.5.2021.

Published under open access CC BY-ND. Downloaded from tidsskriftet.no 24 June 2026.