
A man in his forties with anal tumour and inguinal lymphadenopathy

EDUCATIONAL CASE REPORT

SVETLANA SHARAPOVA

E-mail: aprilsvalex@yahoo.no

Department of Gastrointestinal and Paediatric Surgery

Oslo University Hospital

Svetlana Sharapova, specialty registrar in general surgery and gastrointestinal surgery, and acting consultant.

The author has completed the ICMJE form and declares no conflicts of interest.

USHA HARTGILL

Olafia Clinic

Department of Venereology

Oslo University Hospital

Usha Hartgill, specialist in dermatological and venereal diseases, head of department and senior consultant.

The author has completed the ICMJE form and declares no conflicts of interest.

PREMNAATH TORAYRAJU

Olafia Clinic

Department of Venereology

Oslo University Hospital

Premnaath Torayraju, specialty registrar in the Department of Medicine at Diakonhjemmet Hospital, specialising in dermatological and venereal diseases.

The author has completed the ICMJE form and declares no conflicts of interest.

BETTINA ANDREA HANEKAMP

Department of Radiology

Oslo University Hospital

Bettina Andrea Hanekamp, specialist in radiology, and senior consultant in the Section for Oncological and Abdominal Imaging.

The author has completed the ICMJE form and declares no conflicts of interest.

SIGURD FOLKVORD

Department of Gastrointestinal and Paediatric Surgery

Oslo University Hospital

Sigurd Folkvord, PhD, senior consultant and specialist in gastrointestinal surgery.

The author has completed the ICMJE form and declares no conflicts of interest.

A man in his late forties was examined for suspected cancer of the anal canal with spreading to inguinal lymph nodes. When biopsies failed to confirm malignant disease, other differential diagnoses had to be considered.

A previously healthy man in his late forties consulted his doctor about a lump in his anus. He believed it had been there for about a year, but had not been bothered by it and had assumed that it was a haemorrhoid. In recent weeks, however, he had noticed rectal discharge, initially clear but later blood-tinged, and for the past two weeks he had also been aware of a painful lump in his left groin. He felt weak and had experienced night sweats, but his appetite was good and his weight was stable. The general practitioner found a solid, non-tender left-sided perianal tumour the size of a marble, which extended from the anus up to the pectinate line. It was unclear whether this was the same tumour the patient himself had detected previously. The patient was referred to the gastrosurgical outpatient clinic on suspicion of a possible tumour or thrombosed haemorrhoid. It was stated in the referral that the patient had sex with men.

Five days later, the patient was examined at the gastrosurgical outpatient clinic on the oncology clinical pathway, since malignancy could not be ruled out from the referral.

Anorectal examination and anorectoscopy revealed a solid tumour with central ulceration in the lower part of the anal canal in the 3–5 o'clock position, as described by the general practitioner. The tumour appeared to be growing into the sphincter. In addition, two smaller non-specific lesions were found in the middle part of the rectum. All three lesions were biopsied.

Medium-sized haemorrhoids were also observed. A palpable 4 × 2 cm tender mass in the left groin was considered to be an enlarged lymph node.

A malignant tumour in the anal canal with metastasis to the groin was suspected, and the patient was referred for further testing.

Initial blood tests were normal, including CEA of 1.3 mcg/L (< 5.0). Two days after his initial contact with the healthcare service, the patient underwent a colonoscopy, which was normal except for the known changes in the lower anal canal. The histology results for the biopsies were available after a week. The rectal biopsies showed rectal mucosa with intestinal spirochaetosis, but no signs of malignancy. The biopsies from the perianal tumour showed chronic active plasma cell-rich inflammation, again with no signs of malignancy. Ten days later, a pelvic MRI revealed a suspected malignant tumour of size 1.6 × 0.7 × 3.5 cm at 12–3 o'clock in the lower anal canal that appeared to be affecting the internal anal sphincter (Figure 1).

Lymphadenopathy was also seen along the left common iliac vein and artery, in the mesorectum and in the left inguinal region (Figure 2). The largest left inguinal lymph node was 2.0 × 5.4 cm. CT thorax/abdomen/pelvis revealed lymphadenopathy along the left common iliac vein and artery and in the para-aortic region, but no other signs of metastases.

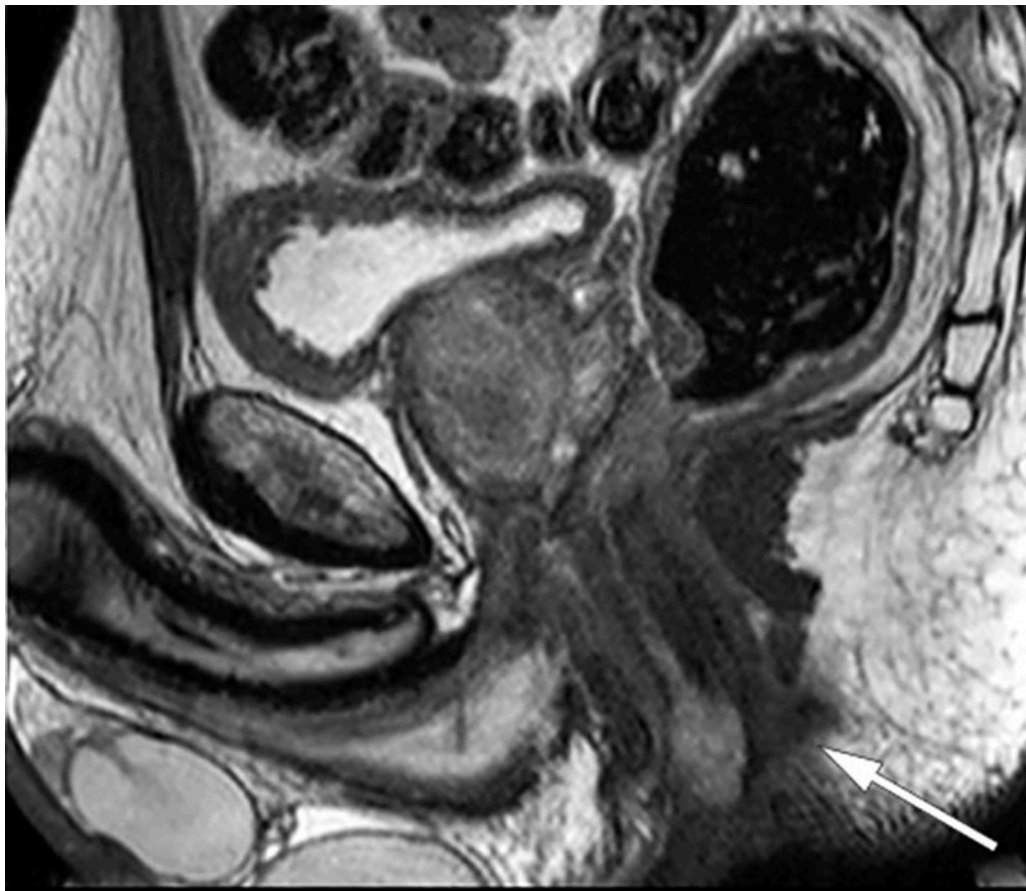


Figure 1 MRI, sagittal view of pelvis. Tumour can be seen in the lower anal canal (arrow).

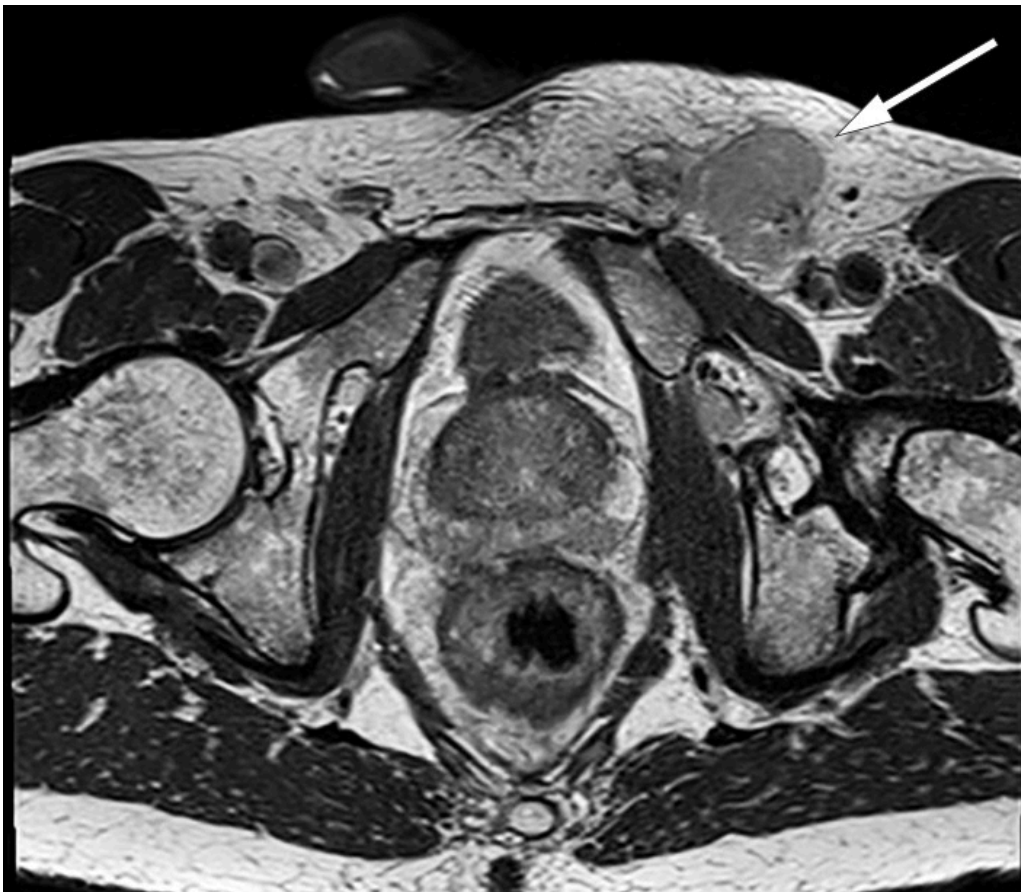

Figure 2 MRI, axial view of pelvis, with enlarged lymph node in left inguinal region (arrow).

Men who have sex with men are at increased risk of anal cancer (1). The clinical and radiological findings suggested anal cancer with spreading to regional and non-regional lymph nodes, but none of the biopsies showed evidence of malignancy. Suspecting that the initial biopsies might not have been representative, we decided to re-biopsy both the tumour and the pathological left inguinal lymph nodes under general anaesthesia. The clinical significance of the intestinal spirochaetosis in the rectal mucosa was unclear. We therefore consulted a specialist in the Department of Venereology (Olafia Clinic) who, on the basis of the symptoms and clinical findings, suggested that sexually transmitted infections could be among the differential diagnoses. It was therefore agreed that the patient would be referred for assessment in the Department of Venereology in parallel with further testing for malignancy. We were advised by the venereologist to send parts of the biopsies to be tested for *Neisseria gonorrhoeae*, *Treponema pallidum*, *Chlamydia trachomatis*, Lymphogranuloma venereum and *Mycoplasma genitalium*.

An excisional biopsy was performed under general anaesthesia, in which the majority of the tumour in the anal canal was removed. During the same operation, an ultrasound-guided biopsy of the enlarged left inguinal lymph node was also performed. The biopsies were sent for histological examination with respect to possible malignancy and for microbiological testing for agents associated with sexually transmitted infections.

The patient received an appointment at the venereology outpatient clinic eleven days after his initial examination in the surgical department. A detailed sexual history was recorded, in which it emerged that the man

practised receptive anal intercourse. Two months earlier, he had been tested for sexually transmitted infections eight days after potential exposure, but the results had been negative. New samples were now obtained to test for sexually transmitted diseases, including perianal wound secretions which were sent for PCR testing for Herpes simplex types 1 and 2, Treponema pallidum and Chlamydia trachomatis; anal swabs for Neisseria gonorrhoeae and Chlamydia trachomatis, a pharyngeal swab for Neisseria gonorrhoeae, blood samples for HIV and syphilis, as well as a urine sample for Neisseria gonorrhoeae and Chlamydia trachomatis.

The patient tested positive for Chlamydia trachomatis in both the wound secretion and the anal swab. Subtyping revealed serovars L1–L3, otherwise known as lymphogranuloma venereum (LGV). The other samples taken at the venereology clinic were negative. The biopsy from the anal canal showed no signs of dysplasia or malignancy, but was positive for Chlamydia trachomatis DNA and Lymphogranuloma venereum DNA. The inguinal lymph node biopsy showed no signs of malignancy either.

The gastrointestinal surgeon and venereologist discussed the test results, and the venereologist concluded that all of the findings could be explained by lymphogranuloma venereum. Representative biopsies had shown no signs of malignancy, and we therefore chose to treat the condition as an infectious disease.

The patient began treatment with doxycycline 200 mg daily for 21 days in accordance with European guidelines (2), with rapid relief of symptoms and regression of the left inguinal lymphadenopathy. When followed up by telephone by the gastrointestinal surgeon, the patient reported that all of his symptoms had resolved. Another anorectoscopy was therefore deemed unnecessary.

Discussion

The initial work-up suggested that the patient had anal cancer with metastases to inguinal, pelvic and para-aortic lymph nodes. Findings from anoscopy and rectal examination, as well as CT and MRI, were consistent with this diagnosis.

Just under 100 cases of anal cancer are diagnosed in Norway annually, of which about 70 % are in women. The median age at diagnosis is 66 years (3). Anal cancer metastasises mainly to regional lymph nodes. Some patients develop metastases in non-regional lymph nodes, and there are also relatively rare cases of distant metastases. Immunosuppression is a predisposing factor, and HIV-positive men are at increased risk of anal cancer, especially among the under 50s (3). Men who have sex with men and who practise receptive anal intercourse are at increased risk of developing anal cancer, irrespective of their HIV status (1). Anal human papillomavirus (HPV) infection is associated with the development of anal intraepithelial neoplasia (AIN). Grade 2 and 3 anal intraepithelial neoplasms are collectively referred to as high-grade squamous intraepithelial lesions (HSIL) and are considered to be precancerous changes (1, 4). Men who have sex with men diagnosed with HSIL-AIN3 associated with

HPV16 are at particularly high risk of developing anal cancer (4). Our patient's anamnesis, together with findings on his MRI and CT scans that were typical of anal cancer, strengthened suspicion of this diagnosis.

The patient's biopsies failed to confirm malignancy and provided no evidence of anal intraepithelial neoplasia. An incidental finding of intestinal spirochaetosis in the rectal biopsy, however, led to a change in strategy with respect to assessment. Intestinal spirochaetosis is a common finding in men who have sex with men, and is associated with colonisation of the colon by microorganisms of the genus *Brachyspira*. This genus has several subtypes, of which the most common are *Brachyspira aalborgi* and *Brachyspira pilosicoli* (5, 6). These bacteria are not associated with the spirochaete *Treponema pallidum*, which causes syphilis. Intestinal spirochaetosis is more prevalent in areas where living standards are low. In industrialised countries, men who have sex with men and HIV-positive individuals are at increased risk of colonisation (5). The pathogenic potential of intestinal spirochaetosis is unclear. Some cases of colonisation lead to intestinal symptoms such as diarrhoea, while other cases are asymptomatic (6). Co-infection with other enteropathogenic bacteria, such as *Enterobius vermicularis*, *Helicobacter pylori*, *Shigella flexneri* and *Neisseria gonorrhoeae*, is often seen, which can make it difficult to determine the extent to which symptoms are caused by intestinal spirochaetosis per se (6). The indication for treatment is unclear given that antibacterial treatment with Flagyl can eliminate the bacterium, without fully resolving the symptoms. In our patient, intestinal spirochaetosis was an incidental finding that led to testing for sexually transmitted infections and, ultimately, to the correct diagnosis.

The patient had an infection caused by *Chlamydia trachomatis* serovars L1, L2, L3, which gives rise to the disease lymphogranuloma venereum (LGV). Lymphogranuloma venereum is endemic in parts of Asia, the Caribbean, Africa and South America (7, 8). From the early 2000s, an increasing number of infections have been seen in industrialised countries, and the disease is endemic among men who have sex with men. In the UK, 99 % of cases of lymphogranuloma venereum are detected in men who have sex with men (9). According to the Norwegian Institute of Public Health, 44 cases of lymphogranuloma venereum were detected in Norway in 2018, all of which were in men. The disease was notifiable through the Norwegian Surveillance System for Communicable Diseases (MSIS) in the period 1993–2002 and became notifiable again in 2019 (10).

Most assays for sexually transmitted infections are now based on the Nucleic Acid Amplification Test (NAAT), which has high sensitivity and specificity. However, it is recommended to wait 14 days after possible exposure in order to avoid false negative results (11). Our patient was tested two months prior to contact with the surgical department without any sexually transmitted infection being detected. The negative results of the initial tests at the venereological outpatient clinic can be explained by the fact that the patient was tested during the window period, i.e. before the point at which any infection can be detected.

Lymphogranuloma venereum is primarily a disease of the lymphatic tissue. The most common chlamydia serotypes (A–K) cause infections that are usually confined to the primary infection site, whereas the lymphogranuloma venereum-associated serotypes induce a lymphoproliferative response. The infection then spreads to the lymph nodes that drain the primary infection focus, leading to lymphangitis and necrosis of the nodes. The disease course is divided into three stages: primary, secondary and late infection (12).

In the primary stage, a small wound or papule appears at the site of inoculation after an incubation period of 2–12 days. The patient often has no symptoms and the lesion heals spontaneously a few days later, with the result that the disease often goes unnoticed. The secondary stage occurs after 2–6 weeks, when the infection spreads to the regional lymph nodes. During this phase, the disease may manifest as an inguinal syndrome, anorectal involvement, or rarely as arthritis or perihepatitis. Inguinal syndrome is the result of an inflammatory response in the superficial and deep inguinal lymph nodes. Intense inflammation gives rise to painful, enlarged lymph nodes in the groin, which can perforate and/or lead to abscess formation. Anorectal involvement can give rise to symptoms such as rectal pain, palpable masses, abdominal pain, diarrhoea, fever and tenesmus. Left untreated, lymphogranuloma venereum can lead to anogenital strictures and pelvic fibrosis, supralelevator and ischiorectal abscesses, fistulae, infertility, and genital elephantiasis (8, 12).

Proctitis involves thickening of the intestinal wall that can mimic malignancy, and can be accompanied by pronounced lymphadenopathy (8). Several case studies have been published in which lymphogranuloma venereum was misinterpreted as malignant disease. Radiologically, it can be very difficult to distinguish lymphogranuloma venereum from malignancies such as adenocarcinoma, lymphoma, and lymph node metastases. The symptoms and endoscopic findings may also sometimes resemble inflammatory bowel disease (13). Differential diagnoses therefore include infectious, inflammatory, ischaemic and neoplastic processes (8, 13).

When a patient is referred for suspected malignancy, the focus of the investigation is to confirm or rule out cancer. In this patient, intestinal spirochaetosis in the rectal biopsy led us to contact the venereology department. While this condition could not explain the patient's symptoms, it was the reason we sought advice from a specialist in dermatological and venereal diseases. Interdisciplinary collaboration between specialties that are not usually involved in the same diagnostic process was in this case crucial in enabling a correct diagnosis to be made.

This case report shows the importance of waiting until a patient has been fully assessed before commencing treatment, even when serious disease is suspected. Initiating cancer therapy would have had serious consequences for this patient, both in terms of adverse effects and complications associated with treatment for the suspected cancer, but also potential sequelae due to the infection remaining untreated. The patient went from worrying about incurable cancer to making a full recovery after only a few weeks of antibiotic therapy.

Conclusion

Doctors who investigate anorectal tumours may encounter lymphogranuloma venereum in their careers, and it is therefore important to be aware of this disease, especially when examining men who have sex with men.

The patient has consented to publication of this article.

LITERATURE

1. Palefsky JM, Holly EA, Ralston ML et al. Anal squamous intraepithelial lesions in HIV-positive and HIV-negative homosexual and bisexual men: prevalence and risk factors. *J Acquir Immune Defic Syndr Hum Retrovirol* 1998; 17: 320–6. [PubMed][CrossRef]
2. de Vries HJC, de Barbeyrac B, de Vrieze NHN et al. 2019 European guideline on the management of lymphogranuloma venereum. *J Eur Acad Dermatol Venereol* 2019; 33: 1821–8. [PubMed][CrossRef]
3. Nasjonalt handlingsprogram med retningslinjer for diagnostikk, behandling og oppfølging av analkreft. IS-2868. Oslo: Helsedirektoratet, 2019. https://www.helsedirektoratet.no/retningslinjer/analkreft-handlingsprogram/Analkreft%20-%20Nasjonalt%20handlingsprogram%20med%20retningslinjer%20for%20diagnostikk,%20behandling%20og%20oppf%C3%B8lging.pdf/_/attachment/inline/06408501-5e87-4e0f-8249-d84877f4fca8:eea588d8f71754f56b2a83ab1a7355439f4fb43f/Analkreft%20-%20Nasjonalt%20handlingsprogram%20med%20retningslinjer%20for%20diagnostikk,%20behandling%20og%20oppf%C3%B8lging.pdf Accessed 9.2.2021.
4. Machalek DA, Jin F, Poynten IM et al. Prevalence and risk factors associated with high-grade anal squamous intraepithelial lesions (HSIL)-AIN2 and HSIL-AIN3 in homosexual men. *Papillomavirus Res* 2016; 2: 97–105. [PubMed][CrossRef]
5. Tsinganou E, Gebbers JO. Human intestinal spirochetosis—a review. *Ger Med Sci* 2010; 8: Doc01. [PubMed]
6. Schmiedel D, Epple HJ, Loddenkemper C et al. Rapid and accurate diagnosis of human intestinal spirochetosis by fluorescence in situ hybridization. *J Clin Microbiol* 2009; 47: 1393–401. [PubMed][CrossRef]
7. Promer K, Pillay A, Chi KH et al. A case of inguinal lymphogranuloma venereum imitating malignancy on CT imaging. *Radiol Case Rep* 2019; 14: 581–3. [PubMed][CrossRef]

8. Sullivan B, Glaab J, Gupta RT et al. Lymphogranuloma venereum (LGV) proctocolitis mimicking rectal lymphoma. *Radiol Case Rep* 2018; 13: 1119–22. [PubMed][CrossRef]
9. Alfa-Wali M, Muktar S, Pissas D et al. Unusual case of a rectal tumour. *BMJ Case Rep* 2018; 2018: bcr-2017–223944. [PubMed]
10. Folkehelseinstituttet. Lymphogranuloma venereum (LGV) – veileder for helsepersonell.
<https://www.fhi.no/nettpub/smittevernveilederen/sykdommer-a-a/venerisk-lymfogranulom-lgv---veiled/> Accessed 9.2.2021.
11. Oslo universitetssykehus. Chlamydia trachomatis; behandling og kontroll.
<https://ehandboken.ous-hf.no/document/3671> Accessed 9.2.2021.
12. Mabey D, Peeling RW. Lymphogranuloma venereum. *Sex Transm Infect* 2002; 78: 90–2. [PubMed][CrossRef]
13. Haugstvedt A, Thorvaldsen J, Halsos AM. Lymphogranuloma venereum som ulcerøs proktitt hos menn som har sex med menn. *Tidsskr Nor Lægeforen* 2007; 127: 2094–5. [PubMed]

Publisert: 25 May 2021. *Tidsskr Nor Legeforen*. DOI: 10.4045/tidsskr.20.0722

Received 8.9.2020, first revision submitted 26.11.2020, accepted 9.2.2021.

Published under open access CC BY-ND. Downloaded from tidsskriftet.no 22 June 2026.