

---

# Magnets in the bowel

---

## IMAGES IN MEDICINE

MAGNUS SCHISTAD

Department of Gastrointestinal and Paediatric Surgery  
Oslo University Hospital

Magnus Schistad, specialty registrar.

The author has completed the ICMJE form and declares no conflicts of interest.

HANS SKARI

Department of Gastrointestinal and Paediatric Surgery  
Oslo University Hospital

Hans Skari, PhD, senior consultant and specialist in general and paediatric surgery.

The author has completed the ICMJE form and declares no conflicts of interest.

BEHZAD KHOSHNEWISZADEH

Department of Radiology and Nuclear Medicine  
Oslo University Hospital

Behzad Khoshnewiszadeh, senior consultant and specialist in radiology.

The author has completed the ICMJE form and declares no conflicts of interest.

OLE SCHISTAD

Department of Gastrointestinal and Paediatric Surgery  
Oslo University Hospital

Ole Schistad, senior consultant and specialist in general and paediatric surgery.

The author has completed the ICMJE form and declares no conflicts of interest.

PÅL AKSEL NÆSS

E-mail: paanae@ous-hf.no

Department of Traumatology

Oslo University Hospital

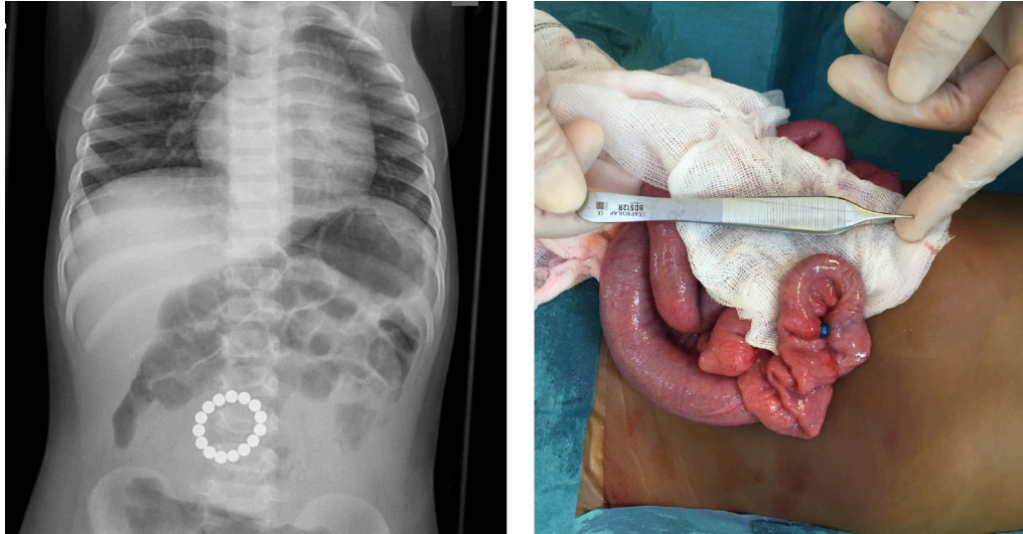
and

Institute of Clinical Medicine

University of Oslo

Professor Pål Aksel Næss, senior consultant and specialist in general and paediatric surgery.

The author has completed the ICMJE form and declares no conflicts of interest.



The X-ray shows a ring of circular foreign bodies inside the abdomen of a one-year-old child. The patient had been admitted with a two-day history of vomiting.

Clinical examination revealed mild abdominal tenderness but no rebound tenderness. Blood tests were normal, with the exception of mild hypochloremic alkalosis and CRP of 25 mg/L (reference range 0–4 mg/L). The patient's mother was shown the X-ray and thought that the object in question might be magnetic beads belonging to a sibling.

The patient underwent laparotomy. A ring of magnetic beads was found in the small intestine about 70 cm from the ligament of Treitz. One of the beads had eroded through the intestinal wall, as can be seen in the perioperative photograph. The magnetic beads were removed, and intestinal resection with primary anastomosis was performed. The patient was discharged on the fifth postoperative day in good general condition, but was readmitted two days later following wound dehiscence. This was surgically corrected, and the child was discharged on the third day after the procedure.

It is not uncommon for young children to swallow foreign bodies. The child's guardians will often be unaware of the incident, and most foreign bodies will pass through the gastrointestinal tract without complications [\(1\)](#). However, ingested magnets can cause life-threatening injury, including obstruction and perforation if the intestinal wall becomes pinched between the magnets, as in

this case and another published previously in this journal (2). If a child is suspected of having swallowed magnets, investigation with an abdominal X-ray is indicated as a first step (3). A chest X-ray will also be indicated if the foreign body could be in the oesophagus.

---

*The patient's next-of-kin have consented to the publication of this article.*

---

## LITERATURE

1. Wright CC, Closson FT. Updates in pediatric gastrointestinal foreign bodies. *Pediatr Clin North Am* 2013; 60: 1221–39. [PubMed][CrossRef]
  2. Fjeldsbø WM, Aukland SM, Tjora E. Farlig tiltrekning. *Tidsskr Nor Legeforen* 2014; 134: 1244. [PubMed][CrossRef]
  3. Hussain SZ, Bousvaros A, Gilger M et al. Management of ingested magnets in children. *J Pediatr Gastroenterol Nutr* 2012; 55: 239–42. [PubMed][CrossRef]
- 

Publisert: 11 December 2020. *Tidsskr Nor Legeforen*. DOI: 10.4045/tidsskr.20.0460

Received 19.5.2020, first revision submitted 17.10.2020, accepted 26.10.2020.

Copyright: © Tidsskriftet 2026 Downloaded from tidsskriftet.no 24 June 2026.