

---

# Medical management of fistulising Crohn's disease

---

## CLINICAL REVIEW

TORE GRIMSTAD

E-mail: [tore.bjorn.grimstad@sus.no](mailto:tore.bjorn.grimstad@sus.no)

Gastroenterology Section

Stavanger University Hospital

Tore Grimstad is a specialist in internal medicine and gastroenterology. He is a senior consultant and post-doctoral researcher. He contributed to the drafting, revision and completion of the manuscript.

The author has completed the ICMJE form and reports the following conflicts of interest: he has received research funding from AbbVie and Tillots Pharma.

ARNE CARLSEN

Gastroenterology Section

Stavanger University Hospital

Arne Carlsen is a specialist in internal medicine and undergoing specialisation in gastroenterology. He contributed to the drafting and revision of the manuscript and approval of the final version.

The author has completed the ICMJE form and reports no conflicts of interest.

LARS N. KARLSEN

Gastroenterology Section

Stavanger University Hospital

Lars N. Karlsen is a specialist in internal medicine and gastroenterology and head of section. He contributed to the drafting and revision of the manuscript and approval of the final version.

The author has completed the ICMJE form and reports no conflicts of interest.

---

**Up to half of patients with Crohn's disease develop fistulae in the course of the disease. The condition often requires multidisciplinary medical and surgical cooperation. Medical management is essential for reducing symptoms and the need for surgical intervention. In this article we wish to review documentation of the efficacy of medical management of fistulising Crohn's disease.**

Crohn's disease is an inflammatory bowel disease that can affect the whole gastrointestinal canal from the mouth to the anus, but is most frequently located at the transition between small and large bowel. In contrast to ulcerative colitis, the inflammation in Crohn's disease is typically transmural, segmental and can give rise to complications as a result of fibrosis, stricturing and fistulising [\(1\)](#). Fistula formation may cause considerable distress in the form of pain, secretion and incontinence. The treatment offered to patients with fistulising Crohn's disease (fistulising CD) is primarily medical management coupled with surgical intervention. Multidisciplinary collaboration between gastroenterologist, gastroenterology surgeon and radiologist (in some cases also gynaecologist and urologist) is often required for optimal treatment, generally in the form of a fistula team.

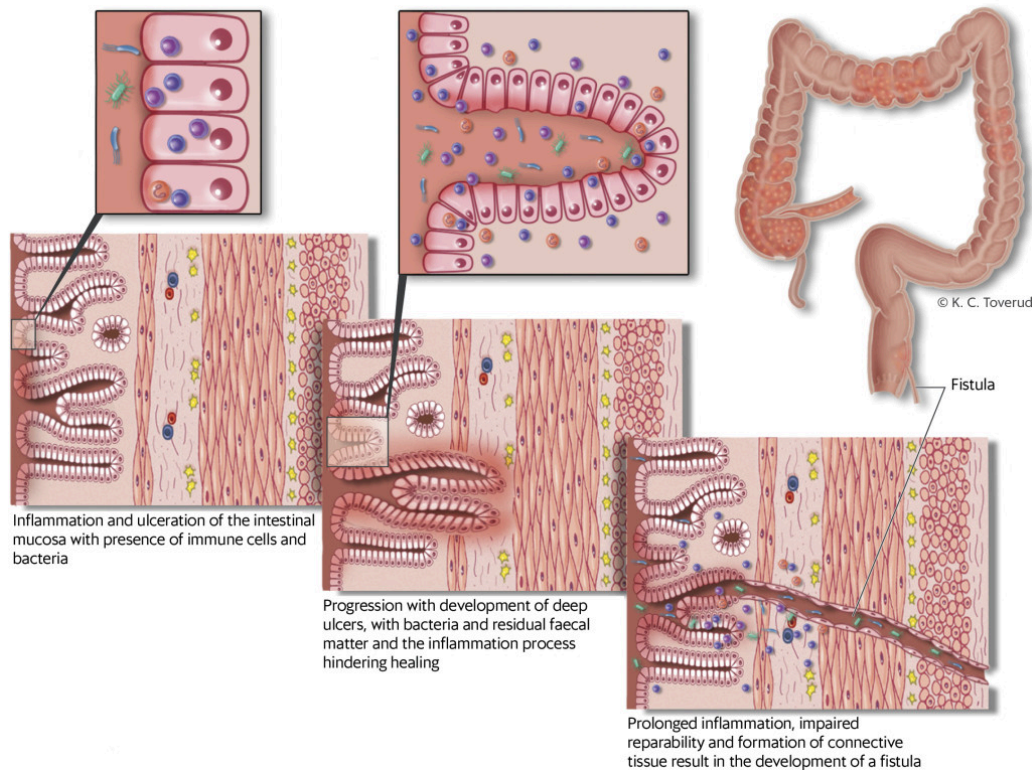
This article presents the main features of medical treatment of fistulising CD, with special emphasis on perianal fistulising. The content is based on an extensive literature search, articles from the authors' own archives and many years of clinical experience in the field.

---

## Definition and clinical aspects

A fistula can be defined as a chronic tract of granulation tissue connecting two epithelium-lined surfaces [\(2\)](#). Fistulising in Crohn's disease affects 15–50 % of patients in the course of the disease. Half of the fistulae are perianal, a quarter enteroenteric and the others vaginal or some other type. In up to 40 % of cases, fistulae have already formed by the time of diagnosis [\(3\)](#).

The assumed pathogenesis of perianal fistula development is that deep ulcers in the intestinal mucosa in which faeces are present provide the starting point for tracts (fistulae) from the mucous membrane to other organs/skin, and that the inflammatory process associated with Crohn's disease is conducive to the formation of ulcers and fistulae (Fig. 1) [\(1\)](#).



**Figure 1** Assumed pathogenesis of fistulising Crohn's disease

Fistulae may start as an abscess causing pain, local swelling and fever, or with secretion and/or faecal incontinence. On suspicion of an abscess, patients must be examined and assessed for immediate surgery because of the risk of tissue damage and septicaemia. If a fistula is suspected or detected, the patient should always be referred to a gastroenterology surgeon. This often takes place after an initial assessment by a gastroenterologist. The fistula type and anatomical extension must be precisely determined. This is achieved by means of clinical examination, endoscopy and diagnostic imaging in the form of endoanal ultrasound and magnetic resonance imaging (MRI) of the pelvis (2).

Fistulising CD often requires combined medical and surgical treatment. After a fistula-related abscess has been drained, the aims are to reduce inflammation and infection, reduce secretion and close the fistula. In some cases, surgical fistulectomy or fistulotomy can be performed on perianal fistulae. Non-cutting Seton string is used after abscess surgery to ensure further drainage. Several repair techniques can be attempted, such as covering the inner fistula opening and at the same time preserving the sphincter muscle by means of an advancement flap.

The long-term goal is to avoid more extensive surgical interventions such as proctectomy and creation of a stoma. Except in the case of an abscess, surgery is seldom the first choice of treatment. It is usually desirable to start with medical fistula management, to curb both inflammatory activity, which often causes the formation of fistulae, and the accompanying secretion and symptoms, which are very distressing for the patient.

In studies on medical management of fistulae in Crohn's disease, the therapeutic response is frequently defined as *fistula response*: secretion from the fistula reduced by at least 50 % or *complete response/healing*: cessation of

secretion from the fistula.

---

## Medical management

### Biologic therapy

Biologic therapy with the tumour necrosis factor inhibitors (TNF- $\alpha$ -inhibitors) infliximab or adalimumab appears to offer the most effective medical management of fistulising CD.

The infliximab study published in 1999 is the only randomised, controlled intervention study using a biologic agent with fistula response as primary end-point. In this study, 94 patients were randomised to either infliximab induction treatment, with infusion at 0, 2 and 6 weeks, or placebo, then infusion in week 14 and evaluation in week 18. Fistula response at two consecutive visits was 62 % in the treatment group and 26 % in the control group (4). The efficacy after 54 weeks of maintenance treatment was also investigated later. In one study, 306 patients received normal induction treatment until week 14, before being randomised for further treatment with 5 mg/kg every eight weeks or a placebo. Patients treated with infliximab had a higher rate of complete fistula response, with 36 % against 19 % (5).

Adalimumab also had some efficacy in a study of 117 patients treated for 56 weeks. The efficacy, measured as a reduction in the number of draining fistulae, was significantly higher in the treatment group after 26 weeks (33 % compared with 13 %) and the results persisted until week 56 (6). Certolizumab pegol is not approved for use with Crohn's disease in Norway, but in a sub-study of 54 respondents after 6 weeks on induction treatment, a significant fistula closure effect was noted after 26 weeks of treatment compared with a placebo (7).

Vedolizumab, a bowel-specific anti-integrin, has exhibited an anti-inflammatory effect in connection with Crohn's disease, and in a sub-analysis of 35 patients with fistulising CD, a significant difference in complete fistula response was found after 52 weeks of treatment, 41 % compared with 11 % for the placebo group (8).

Ustekinumab blocks interleukin 12 and 23. Its efficacy with fistulising CD has not been thoroughly investigated, but a Spanish cohort study with 18 fistula patients, 11 of whom had fistula response after ten months of treatment, indicates that this drug, too, may have some efficacy (9).

Pilot studies with local injection of infliximab or adalimumab in and/or around the fistula area have shown a response rate to fistulising CD of from 40 % to 100 % (10).

### Optimised biologic therapy

Better results have been obtained with higher serum concentrations of infliximab in Crohn's patients. In a recently published cross-sectional study of 117 patients with fistulising CD, the trough level of the drug after 24 weeks of treatment was significantly higher in patients in whom fistula secretion had

ceased, 15.8 mg/l compared with 4.4 mg/l. When the trough levels were stratified by quartiles, higher levels were also found to be associated with improved fistula response, fistula closure and mucosal healing (11). This indicates that the level of the drug in serum should be higher for fistulising CD than for luminal CD (11).

### **Immunomodulatory/immunosuppressant treatment**

Treatment with thiopurine appears to have some efficacy. There is not yet a sufficient scientific basis for other immunosuppressants, such as cyclosporine and tacrolimus, to have an established role in fistula treatment.

Azathioprine and 6-mercaptopurine (thiopurines) were investigated in a randomised controlled study in which 31 % of treated patients had fistula closure compared with 6 % of placebo patients (12). In a meta-analysis of a total of 70 patients with fistulising CD, 54 % of the treatment group exhibited fistula response compared with 21 % in the placebo group after at least six months of treatment (13).

In a retrospective study with 16 patients, methotrexate 25 mg/week produced fistula response in 56 % of patients after three months (14). Another study with an average dose of 18 mg/week for at least six months produced fistula response in 44 % of patients (15). Cyclosporine has proved efficacious against fistulising CD in small patient series, with a response rate of up to 88 % (16). However, the use of cyclosporine is contentious because of potential severe side effects and a high rate of relapse after cessation of treatment (17).

Tacrolimus has been investigated in a randomised controlled trial with 48 patients over 10 weeks, in which 43 % of the treated patients compared with 8 % of the placebo patients achieved fistula response. Here, too, side effects were reported (18).

### **Treatment with a drug combination**

In a study that included 49 patients with fistulising CD, antibiotics in the form of ciprofloxacin and/or metronidazole were administered for eight weeks. Twenty-nine of the participants were additionally treated with azathioprine, either from study start or from week 8. After 20 weeks, 48 % of the patients treated with the drug combination had fistula response compared with only 15 % of the patients who received antibiotics alone (19). Combination treatment accordingly appears to be most appropriate for thiopurines, particularly because of their slow onset effect (19).

Infliximab and ciprofloxacin have been trialled in a randomised controlled study with 24 Crohn's patients, all of whom received infliximab, while ciprofloxacin was administered for the first 12 weeks. After 18 weeks, the combination group had significantly reduced perianal symptoms and a tendency (not significant) towards a reduction in the number of draining fistulae (20).

Adalimumab and ciprofloxacin were combined in a study with 76 patients, in which one group received ciprofloxacin for the first 12 weeks in addition to adalimumab. The follow-up time was 24 weeks. After 12 weeks there was a

significant reduction in fistula secretion and several patients in the antibiotics group exhibited complete cessation of fistula secretion. However, these differences were no longer present on the conclusion of the study (21). In other words, combination treatment with TNF inhibitor and antibiotics has a favourable effect, but this appears to be transitory.

Of 41 patients with Crohn's disease and fistulae who were treated with infliximab or adalimumab combined with azathioprine/6-mercaptopurine, 58 % achieved remission or fistula response after three years of treatment. Early response (after six weeks) was a predictor of early remission of fistulising CD, while only 43 % of patients remained in remission after cessation of TNF inhibitor (22). The combination of TNF inhibitor and immunomodulator has proved to be more efficacious than monotherapy with each of the drugs in luminal Crohn's disease. This appears to be primarily attributable to the formation of antibodies to the drugs. It is reasonable to anticipate a favourable effect also in patients with fistulising CD.

## Antibiotics

Ciprofloxacin in doses of 1 000 mg per day and/or metronidazole 1 000–1 500 mg per day for 8–12 weeks were used in a number of patient series in the 1980s and 1990s. The fistula response in small uncontrolled datasets of 8–21 patients is given as 60–100 % (23–25). However, in a randomised controlled study with 25 patients there was no significant difference in fistula secretion or closure between patients treated with ciprofloxacin, metronidazole or a placebo (26).

A meta-analysis from 2015 of three studies with a total of 112 patients with fistulising CD reported a significant effect (RR 1.66; 95 % CI 1.16–2.39,  $p = 0.006$ ) in favour of ciprofloxacin compared to a placebo or metronidazole for achieving remission of fistulising CD (27).

Although the evidence is not solid, international guidelines prescribe antibiotics as first-line treatment. Monotherapy is seldom an option due to the complexity of Crohn's disease, and biologic therapy is often considered early. Antibiotics appear to have a symptomatic effect, but because of the considerable risk of recurrence and increasing resistance to antibiotics, it is most advisable to combine them with other anti-inflammatory drugs. In clinical practice, treatment seldom exceeds 4–6 weeks. There are no clear recommendations with respect to treatment duration.

Table 1 presents a selection of studies that we regard as central in terms of different types of medical treatment for fistulising CD.

---

### Table 1

Selected studies of different types of medical management of fistulising Crohn's disease, by publication year. OR = odds ratio.

First author, year (reference)	Intervention	Design	Duration (weeks)	Number of participants (n)	Main findings (* = significant difference)
Pearson, 1995 (13)	Azathioprine/6-mercaptopurine vs placebo	Meta-analysis	8-52	70	Fistula response: 54 % vs 21 %, OR 4.4 (1.5-13.2)*
Present, 1999 (16)	Infliximab vs placebo Induction study	Randomised controlled study	18	94	Fistula response: 62 % vs 26 %* Complete response: 46 % vs 13 %*
Dejaco, 2003 (19)	Ciprofloxacin/metronidazole with/ without azathioprine	Randomised controlled study	20 (Antibiotics weeks 0-8)	49	Fistula response: 48 % with azathioprine vs 15 % without azathioprine*
Sands, 2004 (5)	Infliximab vs placebo Maintenance study	Randomised controlled study	54	306	Fistula response: 46 % vs 23 %* Complete response 36 % vs. 19 %*
Thia, 2009 (26)	Ciprofloxacin vs metronidazole vs placebo	Randomised controlled study	10	25	No significant difference between the groups
Colombel, 2009 (6)	Adalimumab vs placebo	Randomised controlled study	56	117	No. of secreting fistulae: 0.88 vs 1.32 (patients vs placebo)* Complete response: 30 % vs 13 %*
Dewint, 2014 (21)	Adalimumab + ciprofloxacin vs adalimumab	Randomised controlled study	24	76	Fistula response: 71 % vs 47 % (12 weeks)* Fistula closure: 65 % vs 33 % (12 weeks)* Week 24: no significant difference

First author, year (reference)	Intervention	Design	Duration (weeks)	Number of participants (n)	Main findings (* = significant difference)
Yarur, 2017 (11)	Infliximab (different serum concentrations)	Retrospective observation study	24	117	Complete response vs no response: s-infliximab 15.4 mg/l vs 4.4 mg/l* Infliximab antibodies gave lower OR for complete response:

---



---

## Summary

Fistula formation in Crohn's disease is a difficult condition to treat, and therapy often has to be customised because of the great variation in presentation forms. Biologic therapy has the best documented effect on fistulising CD, and should probably be administered in a higher dose than for luminal CD.

Immunomodulators (thiopurines) have some effect. Antibiotics may be beneficial for a limited treatment period, but should be combined with biologics or immunomodulators for an enhanced treatment response. Medical treatment alone is seldom advisable, but can often be started in advance of surgery and continued after an intervention. In most cases, a combination of surgery and medical therapy yields the best result, but the ideal strategy or composition of such treatment has not been determined.

---

## LITERATURE

1. Nielsen OH, Rogler G, Hahnloser D et al. Diagnosis and management of fistulizing Crohn's disease. *Nat Clin Pract Gastroenterol Hepatol* 2009; 6: 92–106. [PubMed][CrossRef]
2. Gecse K, Khanna R, Stoker J et al. Fistulizing Crohn's disease: Diagnosis and management. *United European Gastroenterol J* 2013; 1: 206–13. [PubMed][CrossRef]
3. Schwartz DA, Loftus EV, Tremaine WJ et al. The natural history of fistulizing Crohn's disease in Olmsted County, Minnesota. *Gastroenterology* 2002; 122: 875–80. [PubMed][CrossRef]
4. Present DH, Rutgeerts P, Targan S et al. Infliximab for the treatment of fistulas in patients with Crohn's disease. *N Engl J Med* 1999; 340: 1398–405. [PubMed][CrossRef]

5. Sands BE, Anderson FH, Bernstein CN et al. Infliximab maintenance therapy for fistulizing Crohn's disease. *N Engl J Med* 2004; 350: 876–85. [PubMed][CrossRef]
6. Colombel JF, Schwartz DA, Sandborn WJ et al. Adalimumab for the treatment of fistulas in patients with Crohn's disease. *Gut* 2009; 58: 940–8. [PubMed][CrossRef]
7. Schreiber S, Lawrance IC, Thomsen OØ et al. Randomised clinical trial: certolizumab pegol for fistulas in Crohn's disease - subgroup results from a placebo-controlled study. *Aliment Pharmacol Ther* 2011; 33: 185–93. [PubMed][CrossRef]
8. Sandborn WJ, Feagan BG, Rutgeerts P et al. Vedolizumab as induction and maintenance therapy for Crohn's disease. *N Engl J Med* 2013; 369: 711–21. [PubMed][CrossRef]
9. Khorrami S, Ginard D, Marín-Jiménez I et al. Ustekinumab for the treatment of refractory Crohn's Disease: The Spanish experience in a large multicentre open-label cohort. *Inflamm Bowel Dis* 2016; 22: 1662–9. [PubMed][CrossRef]
10. Adegbola SO, Sahnun K, Tozer PJ et al. Review of local injection of anti-TNF for perianal fistulising Crohn's disease. *Int J Colorectal Dis* 2017; 32: 1539–44. [PubMed][CrossRef]
11. Yarur AJ, Kanagala V, Stein DJ et al. Higher infliximab trough levels are associated with perianal fistula healing in patients with Crohn's disease. *Aliment Pharmacol Ther* 2017; 45: 933–40. [PubMed][CrossRef]
12. Present DH, Korelitz BI, Wisch N et al. Treatment of Crohn's disease with 6-mercaptopurine. A long-term, randomized, double-blind study. *N Engl J Med* 1980; 302: 981–7. [PubMed][CrossRef]
13. Pearson DC, May GR, Fick GH et al. Azathioprine and 6-mercaptopurine in Crohn disease. A meta-analysis. *Ann Intern Med* 1995; 123: 132–42. [PubMed][CrossRef]
14. Mahadevan U, Marion JF, Present DH. Fistula response to methotrexate in Crohn's disease: a case series. *Aliment Pharmacol Ther* 2003; 18: 1003–8. [PubMed][CrossRef]
15. Soon SY, Ansari A, Yaneza M et al. Experience with the use of low-dose methotrexate for inflammatory bowel disease. *Eur J Gastroenterol Hepatol* 2004; 16: 921–6. [PubMed][CrossRef]
16. Present DH, Lichtiger S. Efficacy of cyclosporine in treatment of fistula of Crohn's disease. *Dig Dis Sci* 1994; 39: 374–80. [PubMed][CrossRef]
17. Klag T, Goetz M, Stange EF et al. Medical therapy of perianal Crohn's disease. *Viszeralmedizin* 2015; 31: 265–72. [PubMed]

18. Sandborn WJ, Present DH, Isaacs KL et al. Tacrolimus for the treatment of fistulas in patients with Crohn's disease: a randomized, placebo-controlled trial. *Gastroenterology* 2003; 125: 380–8. [PubMed][CrossRef]
19. Dejaco C, Harrer M, Waldhoer T et al. Antibiotics and azathioprine for the treatment of perianal fistulas in Crohn's disease. *Aliment Pharmacol Ther* 2003; 18: 1113–20. [PubMed][CrossRef]
20. West RL, van der Woude CJ, Hansen BE et al. Clinical and endosonographic effect of ciprofloxacin on the treatment of perianal fistulae in Crohn's disease with infliximab: a double-blind placebo-controlled study. *Aliment Pharmacol Ther* 2004; 20: 1329–36. [PubMed][CrossRef]
21. Dewint P, Hansen BE, Verhey E et al. Adalimumab combined with ciprofloxacin is superior to adalimumab monotherapy in perianal fistula closure in Crohn's disease: a randomised, double-blind, placebo controlled trial (ADAFI). *Gut* 2014; 63: 292–9. [PubMed][CrossRef]
22. Tozer P, Ng SC, Siddiqui MR et al. Long-term MRI-guided combined anti-TNF- $\alpha$  and thiopurine therapy for Crohn's perianal fistulas. *Inflamm Bowel Dis* 2012; 18: 1825–34. [PubMed][CrossRef]
23. Bernstein LH, Frank MS, Brandt LJ et al. Healing of perineal Crohn's disease with metronidazole. *Gastroenterology* 1980; 79: 357–65. [PubMed]
24. Solomon MJ, McLeod RS, O'Connor BI et al. Combination ciprofloxacin and metronidazole in severe perianal Crohn's disease. *Can J Gastroenterol* 1993; 7: 571–3. [CrossRef]
25. Jakobovits J, Schuster MM. Metronidazole therapy for Crohn's disease and associated fistulae. *Am J Gastroenterol* 1984; 79: 533–40. [PubMed]
26. Thia KT, Mahadevan U, Feagan BG et al. Ciprofloxacin or metronidazole for the treatment of perianal fistulas in patients with Crohn's disease: a randomized, double-blind, placebo-controlled pilot study. *Inflamm Bowel Dis* 2009; 15: 17–24. [PubMed][CrossRef]
27. Wu XW, Ji HZ, Wang FY. Meta-analysis of ciprofloxacin in treatment of Crohn's disease. *Biomed Rep* 2015; 3: 70–4. [PubMed][CrossRef]

---

Publisert: 9 January 2019. Tidsskr Nor Legeforen. DOI: 10.4045/tidsskr.17.1055

Received 1.12.2017, first revision submitted 18.6.2018, accepted 10.10.2018.

© Tidsskrift for Den norske legeforening 2026. Downloaded from tidsskriftet.no 5 July 2026.