
Antiangiogenic treatment of ocular diseases

PERSPECTIVES

EIRIK SUNDLISÆTER

E-mail: eirik.sundlisater@rr-research.no

Eirik Sundlisæter, specialist in ocular diseases and ophthalmologist at Aleris Øyeklinikk in Oslo. He has a PhD in experimental pathology and is a postdoctoral researcher at the Department of Pathology, Oslo University Hospital Rikshospitalet.

The author has completed the ICMJE form and reports the following conflict of interest: He has received lecture fees from Allergan.

CHRISTINE TVEDT

Christine Tvedt, specialist in ocular diseases and ophthalmologist at Aleris Øyeklinikk in Oslo. Her primary interest is in retinal diseases, and her previous experience includes working as a senior consultant at Oslo University Hospital.

The author has completed the ICMJE form and reports the following conflict of interest: She has a paid position on an advisory board for Bayer.

Vascular endothelial growth factor is central to the pathogenesis of a number of ocular diseases. Drugs that inhibit vascular endothelial growth factor have opened up new possibilities for the prevention of visual impairment and blindness.

Pathological angiogenesis and vascular leakage are hallmarks of ocular diseases such as age-related macular degeneration, diabetic retinopathy, retinal vein occlusions and retinopathy in premature infants. The discovery of the role of vascular endothelial growth factor (VEGF) in these ocular diseases, and the subsequent development of anti-VEGF therapy, is a textbook example of the transfer of knowledge from bench to bedside. Before such treatment became

available, ophthalmologists would often have to simply observe the gradual loss of vision in their patients. Today, the prognosis for these patients is much improved.

Vascular endothelial growth factor

Vascular endothelial growth factor A (VEGF-A, often referred to simply as VEGF) belongs to a family of signalling proteins necessary for normal cardiovascular development and homeostasis (1). The growth factor is produced and secreted by most cells of the body and stimulates angiogenesis, i.e. the formation of new blood vessels from existing blood vessels, for example in foetal development, wound healing and muscle growth. At the cellular level, the growth factor promotes the proliferation, migration and survival of endothelial cells, which line the interior surface of blood and lymph vessels. Transcription of the VEGF gene is primarily controlled by hypoxia-inducible factor, a transcription factor activated by low oxygen saturation (2). Depending on whether the tissue oxygen saturation is low or high, hypoxia-inducible factor can either raise or lower the production of vascular endothelial growth factor as appropriate and thereby regulate angiogenesis.

Vascular endothelial growth factor also plays a key role in pathological ocular angiogenesis. One of the first VEGF inhibitors was developed and approved for the treatment of wet age-related macular degeneration, an ocular disease characterised by leakage and haemorrhage from neovascularisations in the macula, the area of the retina responsible for high-acuity vision (3). The list of ocular indications for treatment with VEGF inhibitors has subsequently been expanded to include macular oedema secondary to retinal vein occlusions, diabetic macular oedema, myopic choroidal neovascularisation and proliferative diabetic retinopathy. Retinopathy in premature infants is also increasingly treated with VEGF inhibitors (4).

Oncology researcher launches concept of antiangiogenic treatment

In 1971, the 'father of angiogenesis', American doctor and oncology researcher Judah Folkman (1933–2008), hypothesised that the growth of cancerous tumours is dependent on angiogenesis and that inhibiting angiogenesis could have therapeutic potential (5). Folkman believed that cancerous tumours could not exceed 1–2 mm³ without recruiting new blood vessels, and that cancer cells produced and secreted an unknown angiogenic factor. In 1983, the research group of American Harold Dvorak isolated a protein that caused leakage from blood vessels and produced oedema in and around cancerous tumours (6). They named this protein 'vascular permeability factor' (VPF). In 1989, the Italian Napoleone Ferrara succeeded in sequencing and cloning a protein that was given the name VEGF (and subsequently renamed VEGF-A) (7). VPF and VEGF would later prove to be the same molecule. In 2004, the first VEGF

inhibitor, bevacizumab, was approved by the US pharmaceutical authorities for the treatment of colorectal cancer (8). Bevacizumab is a monoclonal antibody that blocks interaction of the growth factor with its receptors. Bevacizumab is approved in Norway for the treatment of multiple forms of cancer and is marketed under the name Avastin.

Growth factor key to vascular eye diseases

Pathological, newly-formed blood vessels have a disorganised architecture, loose cell–cell connections, reduced pericyte coverage and a discontinuous basement membrane (9). This results in leakage, oedema in surrounding tissues, and haemorrhage. Irreversible retinal damage with loss of visual acuity may occur if the macula is affected.

As early as 1956, there was speculation that retinal ischaemia, for example in cases of diabetic retinopathy and retinopathy in premature infants, may trigger production of an unknown factor that stimulates angiogenesis (10). Retinal ischaemia in experimental animals, generated by occluding branch retinal veins with a laser, has subsequently been shown to induce iris neovascularisation (11), with increased levels of vascular endothelial growth factor corresponding to the degree of neovascularisation. A causal role for the growth factor has been demonstrated by injecting it into healthy monkey eyes and showing that this leads to the development of iris neovascularisation a few days later (12). Vascular endothelial growth factor is thus sufficient to induce ocular angiogenesis and is therefore a potential drug target.

Oncology drug safe and effective when injected into eye

At the same time as bevacizumab began to be used in oncology patients, the VEGF inhibitor pegaptanib (Macugen) was approved in the United States for the treatment of wet age-related macular degeneration (3). Pegaptanib neutralises VEGF₁₆₅, one of the four isoforms of vascular endothelial growth factor, and it quickly met with competition. Shortly after its approval for colorectal cancer, bevacizumab was administered to patients with wet macular degeneration. A small study showed a clear improvement in visual acuity, reduced retinal thickness and less leakage from neovascular lesions following intravenous administration of bevacizumab (13). American ophthalmologists then began injecting the drug intravitreally (directly into the vitreous of the eye) (14). Norwegian ophthalmology departments were early adopters of this treatment. Intravitreal injections of VEGF inhibitors proved very effective for the treatment of wet age-related macular degeneration and other ocular diseases, with little risk of complications or adverse effects (15, 16). It is also important to note in this context that the development of optical coherence tomography (OCT) has had great clinical, scientific and economic impact within the field of ophthalmology. Optical coherence tomography is a rapid and

non-invasive technique that uses light waves to image anatomical structures of the eye with micrometre resolution (17) (Figure 1). The technology is currently used in most subspecialties of ophthalmology, but especially in the diagnosis and follow-up of eye diseases affecting the retina and the choroid. Figures 2 and 3 show OCT images of a macula from the same patient with wet macular degeneration before and after initiation of anti-VEGF treatment.

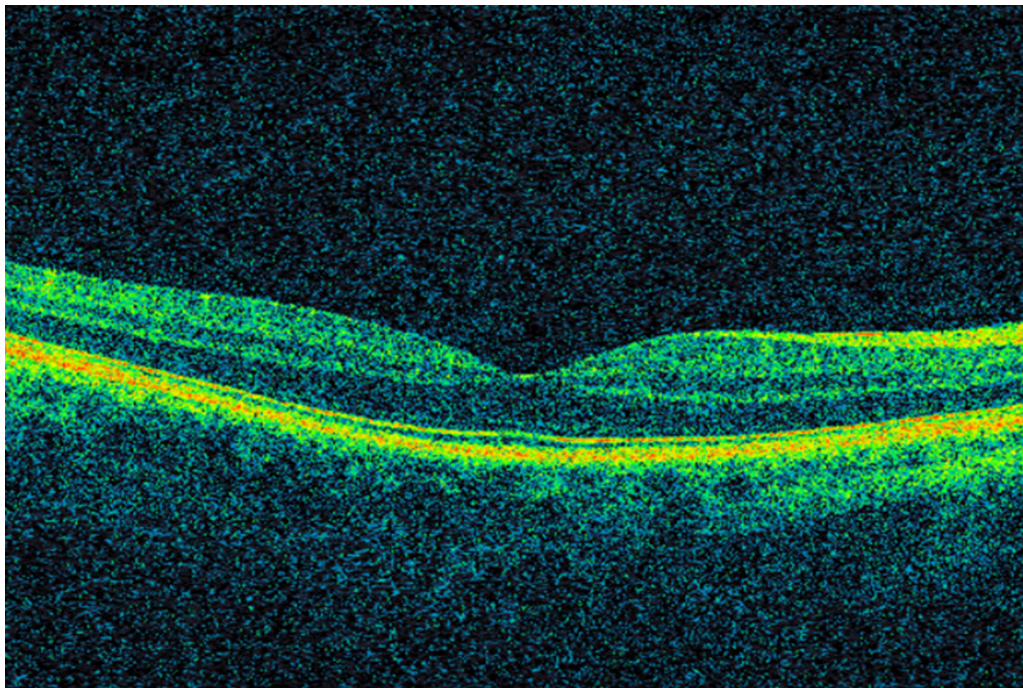


Figure 1 Optical coherence tomography (OCT) showing a normal macula. In the middle, the fovea centralis, which has the highest photoreceptor density. Cross-sectional images of the retina allow assessment of morphology and measurement of retinal thickness.

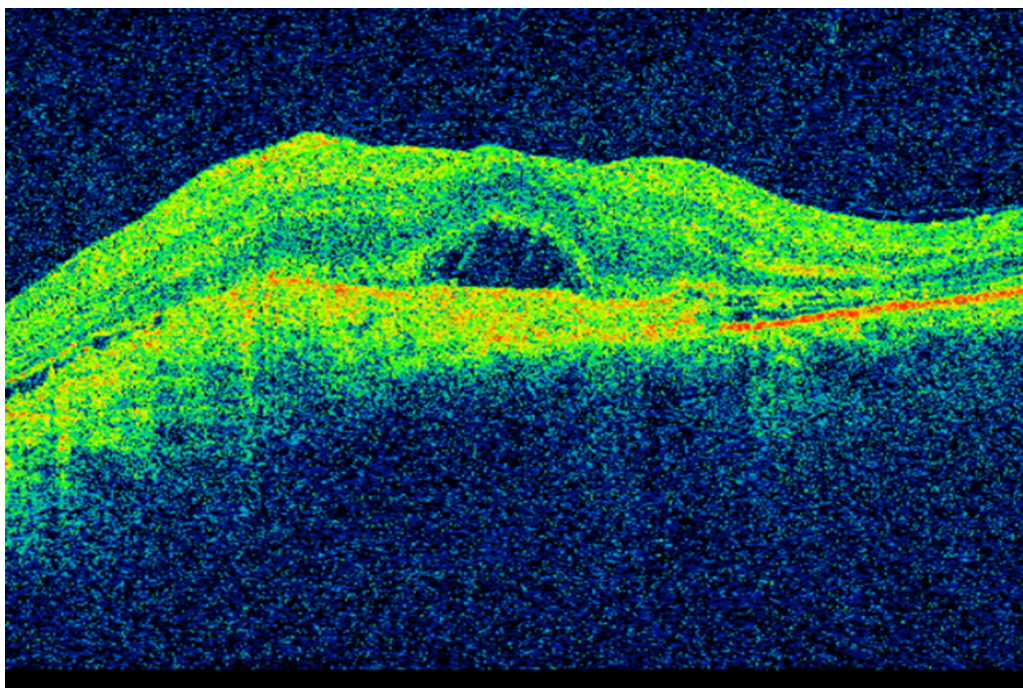


Figure 2 OCT of the macula in a patient with wet age-related macular degeneration prior to initiation of anti-VEGF treatment. Retinal thickening and subretinal fluid can be seen. Visual acuity is 0.1.

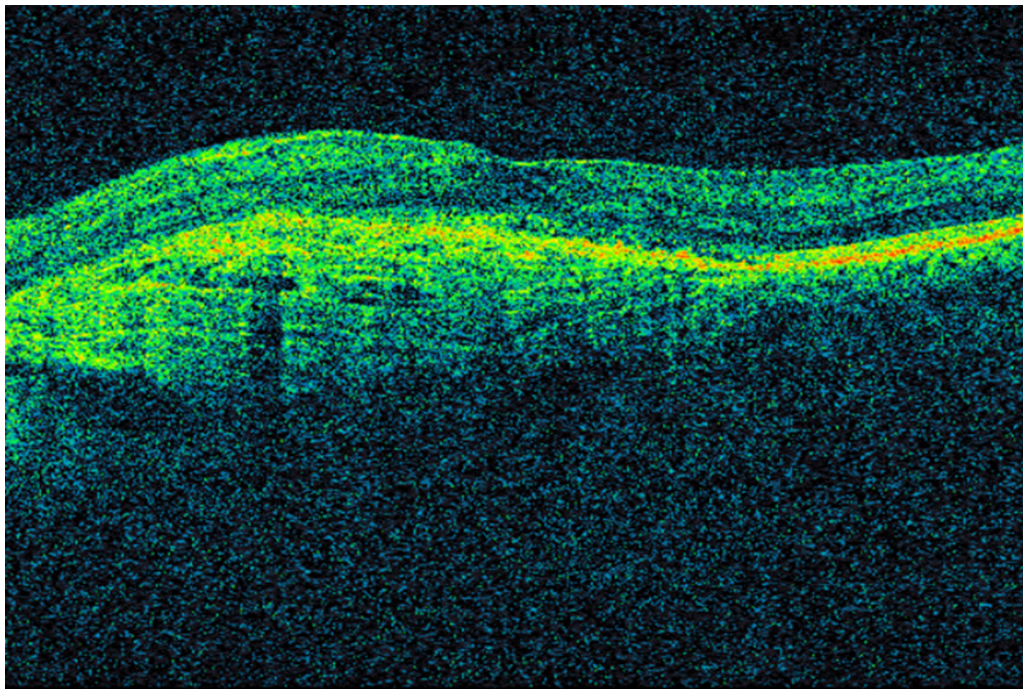


Figure 3 OCT of the macula in the same patient three years later, following repeated anti-VEGF injections. Conditions are now virtually dry. Visual acuity is 0.63.

Bevacizumab is a full-length monoclonal immunoglobulin G (IgG). Based on studies in which full-length antibodies were injected intravitreally into healthy monkey eyes, it had been assumed that the molecular weight of bevacizumab was too high for it to be able to diffuse through the retina and thus reach retinal blood vessels and neovascularisations originating from the underlying choroid (18). The manufacturer of bevacizumab therefore developed a modified variant, ranibizumab (Lucentis), for ocular use. The result was an antigen-binding fragment (a so-called Fab fragment) with higher affinity for vascular endothelial growth factor, lower molecular weight, better tissue penetration and shorter systemic half-life (19). Ranibizumab also lacks the Fc fragment of IgG and does not activate the complement system or platelets. Ranibizumab was approved in 2006 by the US pharmaceutical authorities for the treatment of wet age-related macular degeneration (15). The list of indications has subsequently been expanded.

Although bevacizumab has not been formally approved for ocular use, it is nevertheless used in several neovascular ocular diseases. The main motivation for using bevacizumab is financial: One dose of ranibizumab costs almost NOK 8 000, while a dose of bevacizumab costs NOK 2–300. In 2016, the Department of Ophthalmology at Oslo University Hospital performed more than 20 000 injections of VEGF inhibitors. Savings from the use of bevacizumab would thus be substantial. Studies comparing bevacizumab and ranibizumab have also shown that they are equally effective (20, 21). The initial assumption that intravitreal injection of full-length IgG would not be effective proved to be incorrect. It is likely that in pathological conditions such as age-related macular degeneration, anatomical barriers are defective such that full-length IgG can in fact diffuse through the retina and reach its intended destination. The diffusion studies in monkeys were also performed with antibodies that were subsequently found to bind antigens in the retina, thereby preventing their further diffusion into deeper layers (18).

In addition to pegaptanib and ranibizumab, a third VEGF inhibitor, aflibercept (Eylea), has been approved for ocular use. This is a chimeric fusion protein composed of VEGF receptors 1 and 2 and the Fc portion of human IgG1 (22). Aflibercept binds and blocks VEGF-A, VEGF-B and placental growth factor (PlGF). Compared with ranibizumab and bevacizumab, aflibercept has higher affinity for vascular endothelial growth factor and a longer intravitreal half-life. In practice, three medications are used in intravitreal injections in Norway today: bevacizumab, ranibizumab and aflibercept. Intensive research is being carried out into new and better treatment options, and several exciting drug candidates are undergoing clinical trials. Further knowledge of the mechanisms of vascular eye disease will enable continued drug development and will expand the treatment options available to those patients who, every year, are affected by such conditions.

LITERATURE

1. Ferrara N. Vascular endothelial growth factor: basic science and clinical progress. *Endocr Rev* 2004; 25: 581 - 611. [PubMed][CrossRef]
2. Pugh CW, Ratcliffe PJ. Regulation of angiogenesis by hypoxia: role of the HIF system. *Nat Med* 2003; 9: 677 - 84. [PubMed][CrossRef]
3. VEGF Inhibition Study in Ocular Neovascularization Clinical Trial Group. Pegaptanib for neovascular age-related macular degeneration. *N Engl J Med* 2004; 351: 2805 - 16. [PubMed][CrossRef]
4. VanderVeen DK, Melia M, Yang MB et al. Anti-vascular endothelial growth factor therapy for primary treatment of type 1 retinopathy of prematurity: a report by the American Academy of Ophthalmology. *Ophthalmology* 2017; 124: 619 - 33. [PubMed][CrossRef]
5. Folkman J. Tumor angiogenesis: therapeutic implications. *N Engl J Med* 1971; 285: 1182 - 6. [PubMed][CrossRef]
6. Senger DR, Galli SJ, Dvorak AM et al. Tumor cells secrete a vascular permeability factor that promotes accumulation of ascites fluid. *Science* 1983; 219: 983 - 5. [PubMed][CrossRef]
7. Ferrara N, Henzel WJ. Pituitary follicular cells secrete a novel heparin-binding growth factor specific for vascular endothelial cells. *Biochem Biophys Res Commun* 1989; 161: 851 - 8. [PubMed][CrossRef]
8. Hurwitz H, Fehrenbacher L, Novotny W et al. Bevacizumab plus irinotecan, fluorouracil, and leucovorin for metastatic colorectal cancer. *N Engl J Med* 2004; 350: 2335 - 42. [PubMed][CrossRef]
9. Campochiaro PA. Ocular neovascularization. *J Mol Med (Berl)* 2013; 91: 311 - 21. [PubMed][CrossRef]
10. Wise GN. Retinal neovascularization. *Trans Am Ophthalmol Soc* 1956; 54: 729 - 826. [PubMed]

11. Miller JW, Adamis AP, Shima DT et al. Vascular endothelial growth factor/vascular permeability factor is temporally and spatially correlated with ocular angiogenesis in a primate model. *Am J Pathol* 1994; 145: 574 - 84. [PubMed]
12. Tolentino MJ, Miller JW, Gragoudas ES et al. Vascular endothelial growth factor is sufficient to produce iris neovascularization and neovascular glaucoma in a nonhuman primate. *Arch Ophthalmol* 1996; 114: 964 - 70. [PubMed][CrossRef]
13. Michels S, Rosenfeld PJ, Puliafito CA et al. Systemic bevacizumab (Avastin) therapy for neovascular age-related macular degeneration twelve-week results of an uncontrolled open-label clinical study. *Ophthalmology* 2005; 112: 1035 - 47. [PubMed][CrossRef]
14. Rosenfeld PJ, Moshfeghi AA, Puliafito CA. Optical coherence tomography findings after an intravitreal injection of bevacizumab (avastin) for neovascular age-related macular degeneration. *Ophthalmic Surg Lasers Imaging* 2005; 36: 331 - 5. [PubMed]
15. MARINA Study Group. Ranibizumab for neovascular age-related macular degeneration. *N Engl J Med* 2006; 355: 1419 - 31. [PubMed][CrossRef]
16. Falavarjani KG, Nguyen QD. Adverse events and complications associated with intravitreal injection of anti-VEGF agents: a review of literature. *Eye (Lond)* 2013; 27: 787 - 94. [PubMed][CrossRef]
17. Huang D, Swanson EA, Lin CP et al. Optical coherence tomography. *Science* 1991; 254: 1178 - 81. [PubMed][CrossRef]
18. Mordenti J, Cuthbertson RA, Ferrara N et al. Comparisons of the intraocular tissue distribution, pharmacokinetics, and safety of 125I-labeled full-length and Fab antibodies in rhesus monkeys following intravitreal administration. *Toxicol Pathol* 1999; 27: 536 - 44. [PubMed][CrossRef]
19. Ferrara N, Damico L, Shams N et al. Development of ranibizumab, an anti-vascular endothelial growth factor antigen binding fragment, as therapy for neovascular age-related macular degeneration. *Retina* 2006; 26: 859 - 70. [PubMed][CrossRef]
20. CATT Research Group. Ranibizumab and bevacizumab for neovascular age-related macular degeneration. *N Engl J Med* 2011; 364: 1897 - 908. [PubMed][CrossRef]
21. Berg K, Pedersen TR, Sandvik L et al. Comparison of ranibizumab and bevacizumab for neovascular age-related macular degeneration according to LUCAS treat-and-extend protocol. *Ophthalmology* 2015; 122: 146 - 52. [PubMed][CrossRef]
22. Stewart MW, Gripton S, Kirkpatrick P. Aflibercept. *Nat Rev Drug Discov* 2012; 11: 269 - 70. [PubMed][CrossRef]

Publisert: 5 November 2018. Tidsskr Nor Legeforen. DOI: 10.4045/tidsskr.17.1083
Received 11.12.2017, first revision submitted 19.4.2018, accepted 27.9.2018.
Copyright: © Tidsskriftet 2026 Downloaded from tidsskriftet.no 18 June 2026.