

## Plugs of the air passages

---

### IMAGES IN MEDICINE

MARIUS KALSÅS WORREN

E-mail: [hanmarius@hotmail.com](mailto:hanmarius@hotmail.com)

Marius Kalsås Worren, specialty registrar in the Department of Thoracic Medicine, Haukeland University Hospital.

The author has completed the ICMJE form and reports no conflicts of interest.

ANDERS KJELLEVOLD STORESUND

Anders Kjellevoid Storesund, senior consultant in the Department of Thoracic Medicine, Haukeland University Hospital.

The author has completed the ICMJE form and reports no conflicts of interest.

RAJINDER SHARMA

Rajinder Sharma, senior consultant in the Department of Thoracic Medicine, Haukeland University Hospital.

The author has completed the ICMJE form and reports no conflicts of interest.

OLAV KARSTEN VINTERMYR

Olav Karsten Vintermyr, senior consultant in the Department of Pathology, Haukeland University Hospital and the Gade Laboratory for Pathology, Department of Clinical Medicine, University of Bergen.

The author has completed the ICMJE form and reports no conflicts of interest.

STIG GJERDE

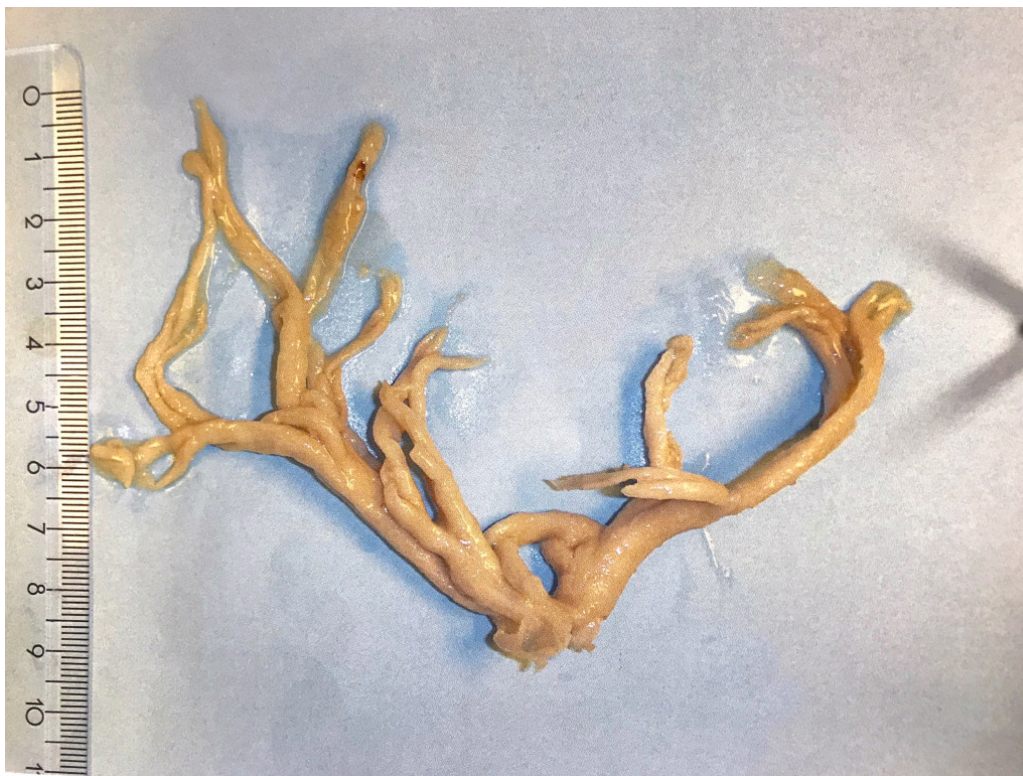Stig Gjerde, senior consultant and head of section in the Department of Anaesthesia and Intensive Care (KSK), Haukeland University Hospital.

The author has completed the ICMJE form and reports no conflicts of interest.

Hans Kristian Flaatten, senior consultant in the Department of Anaesthesia and Intensive Care (KSK), Haukeland University Hospital. The author has completed the ICMJE form and reports no conflicts of interest.

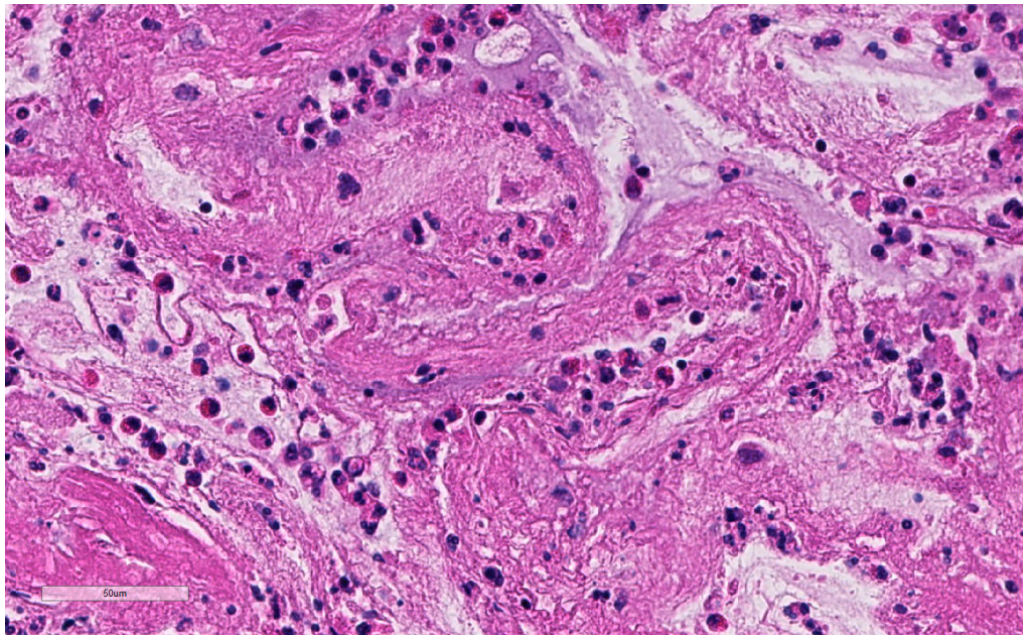
---

A woman in her late thirties was hospitalised owing to cough and dyspnoea. She had previously been examined by her general practitioner, who suspected bronchial asthma. Upon admission, she was judged to have infection-induced asthma exacerbation, and antibiotic and anti-obstructive treatment were initiated. Shortly afterwards she developed severe respiratory failure, and was intubated and transferred to the intensive care department of a university hospital. Owing to difficulty in achieving adequate mechanical ventilation, veno-venous extracorporeal membrane oxygenation (ECMO) was started. During ECMO, bronchoscopy revealed a rubbery material in the trachea. This extended distally into the branches of the bronchial trees of both lungs, with obstruction of large parts of the lumen. The material was removed during the bronchoscopy, from the left lung almost in a single piece. It was found to comprise a rubbery cast of the bronchial tree with a firmer consistency than ordinary mucous plugs (Image 1).



The descriptive diagnosis was plastic bronchitis, which may arise secondary to diseases of the lungs, heart or lymphatic system. A protein- and lipid-rich fluid leaks into the bronchi and forms casts of the bronchial tree (1). The condition is rare, but can occur in all ages and in both sexes. Asthma and atopy are the most commonly associated conditions, second only to surgical correction of congenital heart disease (particularly Fontan surgery). Mortality is estimated at

6–60 %, and the most common cause of death is central airway obstruction (1). The diagnosis is typically made via bronchoscopy. Acute treatment is removal of the cast, either via bronchoscopy or via the patient expectorating the material. The presumed precipitating factor must also be treated.



Microscopy revealed a fibrinous material with abundant eosinophilic granulocytes, but also neutrophilic granulocytes, lymphocytes and plasma cells (Image 2, online). Plastic bronchitis with eosinophilic casts is associated with asthma/atopy or infection with *Aspergillus* (allergic bronchopulmonary aspergillosis/*Aspergillus tracheobronchitis*) (2). In addition to treatment for presumed asthma, our patient also received broad-spectrum antimicrobial treatment, including antifungal coverage. However, no microbes were ever detected, nor any other precipitating factor for plastic bronchitis. The patient's condition improved after removal of the cast. ECMO was discontinued and she was weaned off mechanical ventilation. At follow-up appointments, she has had no respiratory symptoms and has been using no inhaled medicines. Pulmonary function tests yield normal results and bronchoscopy reveals no sign of recurrence. The cause of plastic bronchitis with eosinophilic casts in this patient remains unclear.

---

*The patient has consented to the publication of this article, including images.*

---

## LITERATURE

1. Madsen P, Shah SA, Rubin BK. Plastic bronchitis: new insights and a classification scheme. *Paediatr Respir Rev* 2005; 6: 292 - 300. [PubMed] [CrossRef]
2. Panchabhai TS, Mukhopadhyay S, Sehgal S et al. Plugs of the air passages: a clinicopathologic review. *Chest* 2016; 150: 1141 - 57. [PubMed][CrossRef]

---

Publisert: 10 October 2018. Tidsskr Nor Legeforen. DOI: 10.4045/tidsskr.18.0133  
Received 8.2.2018, first revision submitted 5.7.2018, accepted 27.8.2018.

