Tidsskriftet Tidsskrift for Den norske legeforening

Cerebral hemosiderin deposition

IMAGES IN MEDICINE

STEPHAN JOHANNES SCHÜLER

E-mail: Stephan.Schuler@hnt.no
Department of Neurology
Namsos Hospital
Nord-Trøndelag Hospital Trust
Stephan Johannes Schüler (born 1967), specialist in neurology from Germany, from where he has his dr. med., senior consultant.
The author has completed the ICMJE form and reports no conflicts of interest.

KJELL ARNE KVISTAD

Clinic for Medical Imaging
St. Olavs University Hospital
Kjell Arne Kvistad (born 1960), dr.med., specialist in radiology and senior consultant.
The author has completed the ICMJE form and reports no conflicts of interest.

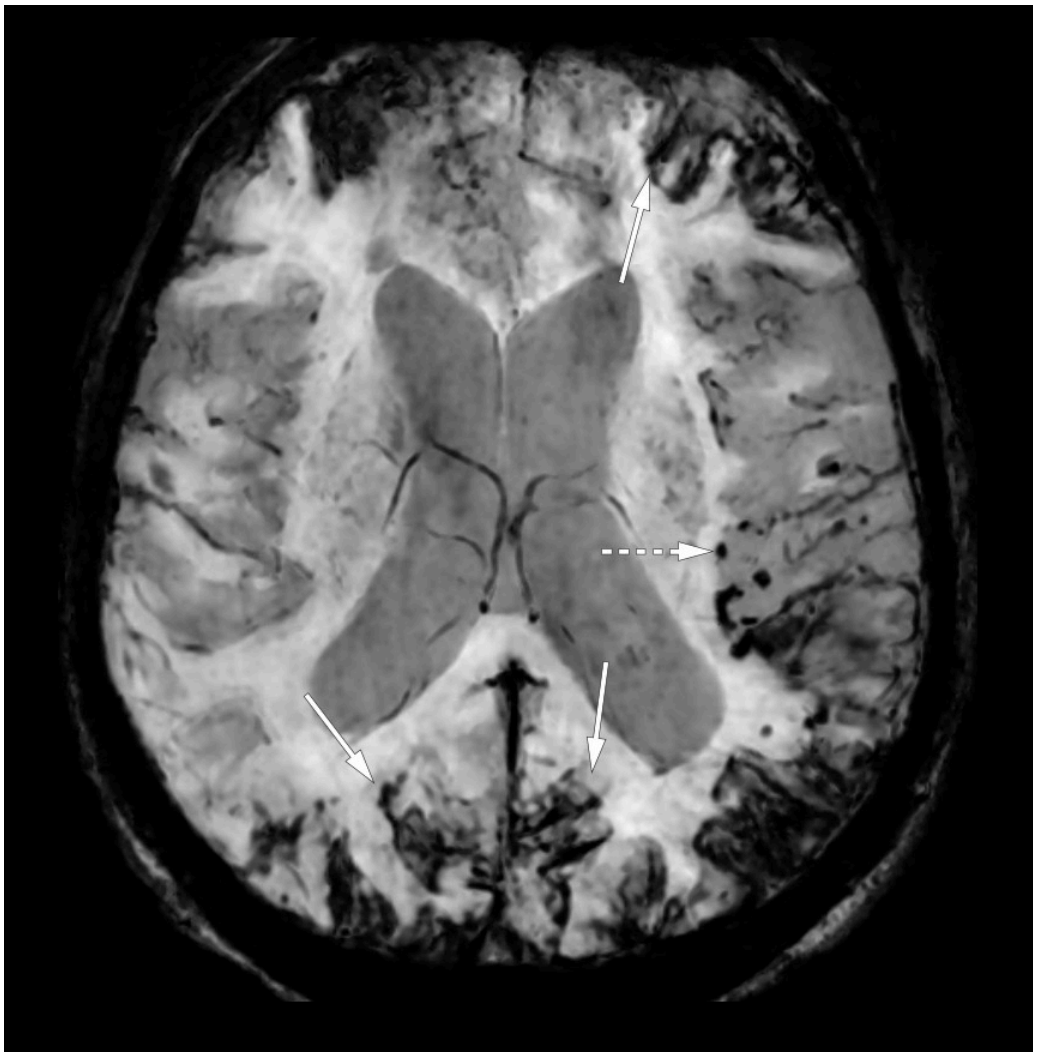

Four years before his hospitalisation, a man in his 90s had a left-sided intraparenchymal cerebral haemorrhage parietally with penetration into the subarachnoid space. Following this, the patient was self-reliant but had moderate cognitive impairments.

Three months before hospitalisation, the patient underwent a gradual decrease in physical and cognitive function that caused him to be bedridden and needing care.

The initial neurological examination did not reveal any definite focal pathology, but the patient appeared confused and aphasic.

CT of the head, thorax, abdomen and pelvis were normal. Lumbar puncture showed no signs of infection or inflammation. The medical history was potentially consistent with Creutzfeldt-Jakob disease, but the 14 – 3-3 protein in cerebrospinal fluid, which is used as a biomarker for the condition, was normal. Beta-amyloid, total tau and phospho-tau in cerebrospinal fluid were consistent with Alzheimer's disease. These are biomarkers used to distinguish Alzheimer's disease from normal ageing. EEG showed generally slow activity (theta), which indicates a non-specific brain disorder.

Susceptibility-weighted MRI in the axial plane showed extensive hemosiderin deposition on the facies cerebralis (solid arrows), consistent with superficial hemosiderosis, numerous microhaemorrhages in the brain parenchyma (dotted arrow), most of these subcortically in the left hemisphere. Microhaemorrhages in connection with a previous haemorrhage are typical of amyloid angiopathy.

Superficial hemosiderosis of the 'classical type' is a rare but potentially serious condition resulting from leptomeningeal hemosiderin accumulation on the surface of the cerebellum, around the cranial nerves and spinal cord. Aetiologically a haemorrhage (acute or chronic) is present in the subarachnoid space.

In the case of the cortical type, hemosiderosis is located supratentorially (above the cerebral convexity), and a cerebral amyloid angiopathy is regarded as an aetiological key factor, particularly in older patients. Cerebral amyloid angiopathy is caused by cerebrovascular amyloid deposition which leads to microaneurysms and an increased tendency to haemorrhage (microhaemorrhages or larger intracerebral parenchymal haemorrhages). Cerebral amyloid angiopathy itself is associated with an elevated risk of developing dementia.

Typical clinical findings for the classical type include hearing loss, ataxia, pyramidal tract signs (spasticity, paralysis) and headache. For the cortical type, (transient) focal neurological symptoms are found, but also development of dementia (1).

Prognostically a slow progression is usually observed for cerebral hemosiderosis, but a rapid deterioration with a fatal outcome has also been described (2).

The pronounced hemosiderosis in this patient is therefore considered to be a contributory cause of the unusually rapid progress of his dementia. The patient died a few months after the diagnosis was made.

The patient's next of kin have consented to the publication of this article.

LITERATURE

1. Charidimou A, Linn J, Vernooij MW et al. Cortical superficial siderosis: detection and clinical significance in cerebral amyloid angiopathy and related conditions. Brain 2015; 138: 2126 - 39. [PubMed][CrossRef]

2. Lanska DJ. Disorders of the special senses in the elderly. I: Nair A, Sabbagh M, red. Geriatric neurology. Chichester, West Sussex: John Wiley & Sons, 2014: 396-459.

Publisert: 21 August 2017. Tidsskr Nor Legeforen. DOI: 10.4045/tidsskr.16.1026
Received 24.11.2016, first revision submitted 31.3.2017, accepted 9.5.2017.
Copyright: © Tidsskriftet 2026 Downloaded from tidsskriftet.no 15 July 2026.